

## รายงานโครงการวิจัยเรื่อง

การศึกษาพยาธิสภาพและพยาธิกำเนิดของโรคเลปโตสไปโรซิสใน  
สัตว์ทดลองที่ได้รับเชื้อเลปโตสไปราที่ผ่านเข้าไปในสัตว์ทดลองจำนวน  
ครั้งต่างกันเพื่อการพัฒนาวัคซีนและการตรวจวินิจฉัย

Study of pathology and pathogenesis of leptospirosis in an animal  
model inoculated with various *in vivo* passages of leptospire :  
implications for vaccine development and diagnosis

คณะผู้วิจัย

รองศาสตราจารย์ ดร. จินตนา จิรถาวร

ผู้ช่วยศาสตราจารย์ แพทย์หญิง ดร. กนิษฐา ภัทรกุล

พันโทสัตวแพทย์หญิงดวงพร พูลสุขสมบัติ

ศาสตราจารย์ นายแพทย์ ยง ภู่วรรณ

ทุนงบประมาณแผ่นดินประจำปีงบประมาณ 2549

## Acknowledgements

We would like to thank the committee of the National Research Council of Thailand, Professor Soottiporn Chittmitrapap and Associate Professor Vilai Chentanez for their consideration on funding this project. We would like to extend our sincere appreciation to Associate Professor Pattama Ekpo, Department of Immunology, Faculty of Medicine, Mahidol University for kindly providing us *Leptospira* stock and for her advice. This project would never have been proceeded in similar direction as originally propose without her help. Finally, we are deeply indebted to Associate Professor Somboon Keelawat and Dr. Amornpun Sereemaspun for their help in pathological examination.

สถาบันวิทยบริการ  
จุฬาลงกรณ์มหาวิทยาลัย

เลขหมู่

เลขทะเบียน 013729

วัน, เดือน, ปี 21ก.ค.51

## Table of Contents

Topics	Page#
Abstract	1
List of Figures	2
Lists of Tables	5
Introduction	6
Materials and Methods	9
Results	13
Discussion and Conclusion	73
References	75



สถาบันวิทยบริการ  
จุฬาลงกรณ์มหาวิทยาลัย

## ABSTRACT

Leptospirosis is a worldwide zoonosis caused by bacteria from the genus *Leptospira*. Several reports have suggested the roles of cytokines in pathogenesis of this infectious disease. In this study, cytokine gene expression in kidneys, livers and lungs was investigated. In addition to host cytokine gene expression, the expression of *Leptospira* genes at target organs was also studied. Golden Syrian hamsters were injected with virulent or avirulent *Leptospira interrogans* serovar Pyrogenes. Kidney, liver and lung tissues were collected for pathological examination and gene expression. RNA was extracted from tissues and RT-PCR was performed to demonstrate the expression of hamster HPRT, TNF- $\alpha$ , TGF- $\beta$ , IL-10 and IP-10 in tissues. For *Leptospira* gene expression, 16S rRNA, LipL21, LipL32 and collagenase gene expression was investigated. Our study provided further information on the immune response to *Leptospira* in infected tissues. Although, the difference in pathologies was observed among hamsters infected with avirulent and virulent *Leptospira*, the correlation of cytokine gene expression could not be strongly concluded from the obtained data. LipL21, Lip32 and collagenase expression in kidney, liver and lung was detected which suggested that they may be involved in survival in infected host. Further experiments such as *in situ* hybridization could demonstrate the roles of both cytokine and *Leptospira* gene expression in pathogenesis in affected organs.

สถาบันวิทยบริการ  
จุฬาลงกรณ์มหาวิทยาลัย

## List of Figures

Figures	Page #
Figure 1 HPRT expression in kidneys, livers and lungs of non-infected hamsters	23
Figure 2 HPRT expression in kidneys from hamsters infected with virulent <i>Leptospira</i>	24
Figure 3 HPRT expression in livers from hamsters infected with virulent <i>Leptospira</i>	25
Figure 4 HPRT expression in lungs from hamsters infected with virulent <i>Leptospira</i>	26
Figure 5 TNF- $\alpha$ expression in kidneys, livers and lungs of non-infected hamsters	27
Figure 6 TNF- $\alpha$ expression in kidneys from hamsters infected with virulent <i>Leptospira</i>	28
Figure 7 TNF- $\alpha$ expression in livers from hamsters infected with virulent <i>Leptospira</i>	29
Figure 8 TNF- $\alpha$ expression in lungs from hamsters infected with virulent <i>Leptospira</i>	30
Figure 9 TGF- $\beta$ expression in kidneys, livers and lungs of non-infected hamsters	31
Figure 10 TGF- $\beta$ expression in kidneys from hamsters infected with virulent <i>Leptospira</i>	32
Figure 11 TGF- $\beta$ expression in livers from hamsters infected with virulent <i>Leptospira</i>	33
Figure 12 TGF- $\beta$ expression in lungs of hamsters infected with virulent leptospira	34
Figure 13 IL-10 expression expression in kidneys, livers and lungs of non-infected hamsters	35
Figure 14 IL-10 expression in kidneys from hamsters infected with virulent <i>Leptospira</i>	36
Figure 15 IL-10 expression in livers from hamsters infected with virulent <i>Leptospira</i>	37
Figure 16 IL-10 expression in lungs from hamsters infected with virulent <i>Leptospira</i>	38
Figure 17 IP-10 expression in kidneys, livers and lungs of non-infected hamsters	39
Figure 18 IP-10 expression in kidneys from hamsters infected with virulent <i>Leptospira</i>	40
Figure 19 IP-10 expression in livers from hamsters infected with virulent <i>Leptospira</i>	41
Figure 20 IP-10 expression in lungs from hamsters infected with virulent <i>Leptospira</i>	42

Figures	Page #
Figure 21 HPRT expression in kidneys from hamsters infected with avirulent <i>Leptospira</i>	43
Figure 22 HPRT expression in livers from hamsters infected with avirulent hamsters	44
Figure 23 HPRT expression in lungs from hamsters infected with avirulent <i>Leptospira</i>	45
Figure 24 TNF- $\alpha$ expression in kidneys from hamsters infected with avirulent <i>Leptospira</i>	46
Figure 25 TNF- $\alpha$ expression in livers from hamsters infected with avirulent hamsters	46
Figure 26 TNF- $\alpha$ expression in lungs from hamsters infected with avirulent <i>Leptospira</i>	47
Figure 27 TGF- $\beta$ expression in kidneys from hamsters infected with avirulent <i>Leptospira</i>	48
Figure 28 TGF- $\beta$ expression in livers from hamsters infected with avirulent hamsters	49
Figure 29 TGF- $\beta$ expression in lungs from hamsters infected with avirulent <i>Leptospira</i>	50
Figure 30 IL-10 expression in kidneys from hamsters infected with avirulent hamsters	51
Figure 31 IL-10 expression in livers from hamsters infected with avirulent hamsters	51
Figure 32 IL-10 expression in lungs from hamsters infected with avirulent hamsters	52
Figure 33 IP-10 expression in kidneys from hamsters infected with avirulent hamsters	52
Figure 34 IP-10 expression livers from hamsters infected with avirulent hamsters	53
Figure 35 IP-10 expression in lungs from hamsters infected with avirulent <i>Leptospira</i>	54
Figure 36 16S rRNA expression in kidneys, livers and lungs from non-infected hamsters	56
Figure 37 16S rRNA expression in kidneys from hamsters infected with virulent <i>Leptospira</i>	57
Figure 38 16S rRNA expression in livers from hamsters infected with virulent <i>Leptospira</i>	58
Figure 39 16S rRNA expression in lungs of hamsters infected with virulent <i>Leptospira</i>	59
Figure 40 16 S rRNA expression in kidneys of hamsters infected with avirulent <i>Leptospira</i>	60
Figure 41 16 S rRNA expression in livers from hamsters infected with avirulent <i>Leptospira</i>	61

Figures	Page #
Figure 42 16 S rRNA expression in lungs of hamsters infected with avirulent <i>Leptospira</i>	62
Figure 43 LipL21 expression in kidneys (A), livers (B) and lungs (C) from non-infected hamsters	63
Figure 44 LipL21 expression in kidneys from hamsters infected with virulent <i>Leptospira</i>	64
Figure 45 LipL21 expression in livers from hamsters infected with virulent <i>Leptospira</i>	64
Figure 46 LipL21 expression in lungs from hamsters infected with virulent <i>Leptospira</i>	65
Figure 47 LipL32 expression in kidneys, liver and lungs from non-infected hamsters	66
Figure 48 LipL32 expression in kidneys from hamsters infected with virulent <i>Leptospira</i>	67
Figure 49 LipL32 expression in livers from hamsters infected with virulent <i>Leptospira</i>	68
Figure 50 LipL32 expression in lungs from hamsters infected with virulent <i>Leptospira</i>	68
Figure 51 Collagenase expression in kidneys, livers, and lungs from non-infected hamsters	69
Figure 52 Collagenase expression in kidneys from hamsters infected with virulent <i>Leptospira</i>	69
Figure 53 Collagenase expression in livers from hamsters infected with virulent <i>Leptospira</i>	70
Figures 54 Collagenase expression in lungs from hamsters infected with virulent <i>Leptospira</i>	70
Figure 55 LipL21, LipL32 and collagenase gene expression in avirulent and virulent <i>Leptospira</i>	71

## List of Tables

Tables	Page #
Table 1 Primer sequences and expected PCR product sizes	11
Table 2 PCR conditions	12
Table 3 Pathologies observed in kidney, liver and lung tissues of hamsters infected with avirulent <i>Leptospira</i>	14
Table 4 Pathologies observed in kidney, liver and lung tissues of hamsters infected with virulent <i>Leptospira</i>	18
Table 5 Comparison of MAT antibody titers between avirulent and virulent group	72



สถาบันวิทยบริการ  
จุฬาลงกรณ์มหาวิทยาลัย



## INTRODUCTION

Leptospirosis is a worldwide zoonosis caused by spirochetes of the genus *Leptospira*. It has been identified as a re-emerging infectious disease in rural and urban environment in both industrialized and developing countries. Leptospirosis is transmitted by direct contact with urine from infected animals or indirect contact with contaminated water. Hematogenous dissemination of *Leptospira* throughout the infected host can result in a wide range of clinical manifestations. Clinical symptoms of leptospirosis vary from subclinical infection to variety of adverse effects. In severe cases, pulmonary hemorrhage, hepatic and renal dysfunction or multiorgan failure can occur and lead to fatality [1-3].

Molecular mechanisms underlying pathogenicity of leptospirosis are not clearly understood. Several virulence factors such as lipopolysaccharide, outer membrane proteins, and various secretory proteins have been studied [4-9]. In addition, immune response to leptospires has been increasingly explored since it may be involved in induction of leptospirosis pathogenesis. For this disease, study of immune response does not only provide information for proper vaccine development but also for further elucidating mechanisms of pathogenesis. An improved understanding of host immune response in leptospirosis may lead to development of more effective treatment and prevention of the disease.

Various studies have demonstrated roles of cytokine induction in immune response to leptospires. *Leptospira borgpetersinii* serovar Hardjo induced IFN- $\gamma$  production by CD4+T cell and  $\gamma\delta$ T cells and *Leptospira interrogans* serovar Rachmati induced IFN- $\gamma$ , IL-12p40, and TNF- $\alpha$  in human whole blood [10, 11]. These data suggested that leptospires induced Th1 cytokine response. Campet et al, supported the role of  $\gamma\delta$ T cells in immune response to *Leptospira* by using lived leptospires to stimulate peripheral blood mononuclear cells. They found that when high number of leptospires was used, majority of expanding cells were  $\gamma\delta$ T cells. However, low number of leptospires induced significant  $\alpha\beta$ T cell expansion instead [12].

Expression of IL-2, IL-4, IL-10, IL-12p40, TNF- $\alpha$ , IFN- $\gamma$ , TGF- $\beta$  in peripheral blood mononuclear cells of hamsters infected with *L. interrogans* serovar Icterohaemorrhagiae were shown using real-time PCR assay [13]. The increase in TNF- $\alpha$ , IFN- $\gamma$ , and IL-12 expression could be detected since a few hours postinfection; however, levels of IL-4 and IL-10, anti-inflammatory cytokines were prominent in delayed samples from 1 to 4 days postinfection.

Immune responses to components of leptospires have also been demonstrated. Glycolipoprotein of *Leptospira interrogans* serovar Copenhagen induced IL-6, IL-10, and TNF- $\alpha$  production in peripheral blood mononuclear cells [14, 15]. Outer membrane protein of *Leptospira interrogans* serovar Shermani induced NF- $\kappa$ B activation and expression of nitric oxide, MCP-1, and TNF- $\alpha$  in medullary thick ascending limb cells [16]. These data suggested that cytokine production may be involved in tuberointerstitial nephritis caused by leptospirosis. Tian et al, [17] demonstrated that outer membrane protein of *Leptospira santarosai* serovar Shermani increased type I and type IV collagens and TGF- $\beta$  in proximal tubular cells and suggested that *Leptospira* may cause renal failure by enhancing extracellular matrix synthesis.

Chemokines are involved in attraction and retention of lymphocytes in infected tissues. Interferon-gamma inducible protein-10 kDa (IP-10) or CXCL-10 is a CXC chemokine which is a T cell chemoattractant. Expression of IP-10 has been found among patients suffering from diseases associated with a type 1 immune response, including tuberculosis, scrub typhus, *Helicobacter pylori* gastritis and chronic viral hepatitis [18-21]. It has been reported that *Leptospira* activated T cell expansion [12]. Plasma IP-10 and Mig (monokine induced by IFN- $\gamma$ ) were higher in patients with definite or possible leptospirosis than in healthy donors [22]. Other chemokines such as monocyte chemoattractant protein-1, neutrophil-chemoattractant chemokines (CXCL1/KC) and CXCL2/MIP-2 were induced by leptospiral outer membrane protein [16, 23, 24].

Most reports on cytokine production in response to leptospires were done using peripheral blood mononuclear cells from infected animals or *in vitro* stimulation of certain cell lines with *Leptospira* or *Leptospira* components. In this study, we

demonstrated the presence of cytokine in kidneys, livers and lungs the organs commonly shown pathologies in leptospirosis patients.

The cytokines investigated in this study were TNF- $\alpha$  since it is a proinflammatory cytokine, IL-10 and TGF- $\beta$  for their roles as anti-inflammatory cytokines and finally, IP-10, a chemokine which may be involved in T cell recruitment to infected organs. Expression of IL-4 and IFN- $\gamma$  were not investigated in this study as we originally proposed since it has been reported by Athanazio et al [25] that mice with IL-4 or IFN- $\gamma$  deficiency showed no difference in survival rate following *Leptospira* infection compared with normal mice.

In addition to cytokine study, the expression of *Leptospira* genes in kidney, liver and lung tissues were investigated. Outer membrane proteins are good candidate for serological diagnosis and vaccine development since its exposure and accessible to host immune system. Various outer membrane proteins (OPM) of *Leptospira* have been identified [4, 26]. LipL32 is the most studied leptospiral outer membrane protein. Immunohistochemistry of infected hamster kidney demonstrated intense LipL32 reactivity in proximal tubule cells and the interstitium which suggested that this protein may be involved in tubulo-interstitial nephritis. Acute and convalescent sera reacted strongly to LipL32. Sequence of LipL32 is highly conserved among pathogenic leptospires [27],[28]. For these reasons, LipL32 has been widely studied as a candidate protein for diagnostic tool and vaccine development [29, 30]. Its role in pathogenesis has also been suggested. LipL32 triggered an inflammatory response in mouse renal proximal tubule cells through a mechanism involving nuclear factor-kB and Toll-like receptor-2 [24, 31].

LipL21 is 21 kDa lipoprotein which expresses *in vivo* and is found only in pathogenic strains. It is the second abundance *Leptospira* OMPs and has been widely studied for laboratory diagnosis development. However, its role in pathogenesis has not been well studied. In addition to OMPs, we are interested in studying the role of *Leptospira* collagenase in tissue pathologies. Collagenase is an extracellular toxin/enzyme. Collagen is an integral component of connective tissues that surrounds most organs. Collagenase hydrolyses collagen molecule which contributes to the loss of tissue integrity. Therefore, collagenase may play a role in tissue destruction.

*Leptospira* collagenase gene has been identified; however, its role in pathogenesis has not been studied.

## MATERIALS AND METHODS

### *Bacteria and Animals*

*Leptospira interrogans* serovar Pyrogenes, and isolate previously shown to induce pathogenesis in hamsters (23) was used in this study. Golden Syrian Hamsters (*Mesocricetus auratus*), age 4-6 weeks were injected intraperitoneally with  $10^8$  *Leptospira interrogans* serovar Pyrogenes. Hamsters were euthanized on days 3, 5 and 7 postinfection (4 hamsters were used for each timepoint). This group of hamsters was injected with the isolate freshly thawed from liquid nitrogen so the isolate was still virulent. This group of animals will be called virulent group.

Four uninfected hamsters were used as a control. In addition, hamsters infected with the same leptospiral isolate that had been previously rendered avirulent by passage in the laboratory were also examined. We found that the isolate that has been passaged *in vitro* has lost its virulent so we included this group of animals for comparison with virulent group. This group of animals was sacrificed on days 3, 7, 14 and 21 postinfection. In this report, this group of hamsters will be called avirulent group whereas the

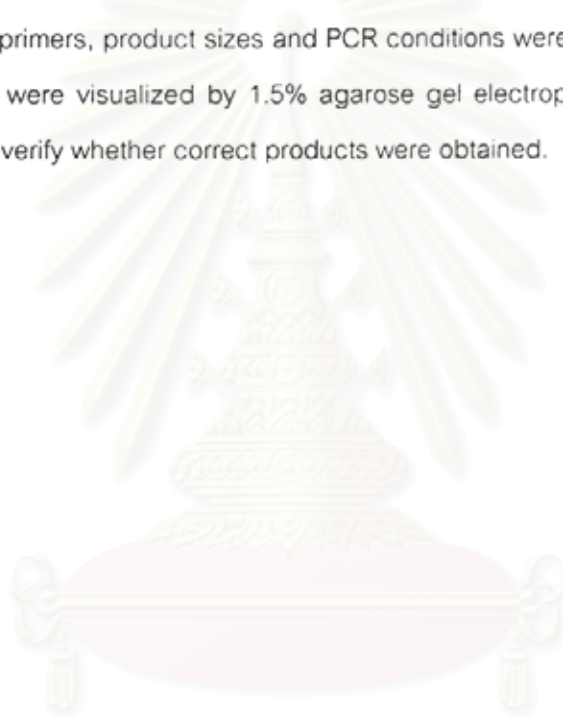
### *Tissue pathology examination*

Kidneys, livers and lungs of hamsters from both virulent and avirulent groups were preserved in 10% formalin. Hematoxylin & Eosin (H & E) staining was performed for tissue pathology examination. The pathologist examined all tissue pathologies without knowing the sources of all slides.

### *RT-PCR*

Tissues for gene expression were preserved in RNA stabilization solution (Qiagen, CA). Total RNA were extracted from 0.01-0.2 g of tissues using TRIzol reagent (Invitrogen, CA) according to manufacturer instruction. One ug of RNA was treated with RNase-free DNase I (Fermentas, MD) for residual DNA removal before using in cDNA synthesis. cDNA synthesis was performed by using random hexamer and M-MuLV reverse transcriptase (Fermentas) at 42°C for 60 min.

Complementary DNA was amplified using primers specific to genes of interest. Sequences of primers, product sizes and PCR conditions were shown in Table 1 and 2. PCR products were visualized by 1.5% agarose gel electrophoresis and sent out for sequencing to verify whether correct products were obtained.



สถาบันวิทยบริการ  
จุฬาลงกรณ์มหาวิทยาลัย

Table 1 Primer sequences and expected PCR product sizes

Primer names		Sequences	Product sizes
HPRT	F	5'-CTGAAGAGCTACTGTAAYGAT-3'	206
HPRT	R	5'-TTTCACCARCAAGYTTGCAA-3'	
TNF- $\alpha$	F	5'-CCCAAAGGGAAGAGAAGTTC-3'	126
TNF- $\alpha$	R	5'-CCACTTGGTGGTTTGCTACA-3'	
TGF- $\beta$	F	5'-CAACTATTGCTTCAGCTCCAC-3'	186
TGF- $\beta$	R	5'-GTASAGGGCMAGGACCTTRCT-3'	
IL-10	F	5'-TGCAGGACTTTAAGGGTTAC-3'	163
IL-10	R	5'-GGGAGAAATCGATGACAGC-3'	
IP-10	F	5'-GAATCCCTCTTTCAAGGACAGT-3'	486
IP-10	R	5'-TAGTAGAGTTGGGGACTCTTGT-3'	
16S rRNA	F	5'-CAAGTCAAGCGGAGTAGCAA-3'	290
16S rRNA	R	5'-CTTAACCTGCTGCCTCCCGTA-3'	
LipL21	F	5'-GCAGCTTGTCCAGTACTGAC-3'	341
LipL21	R	5'-CGATTACAGATGCAGTAGCTTC-3'	
LipL21	RR	5'-GTGGATTGCATCATCGCTTGAC-3'	225
LipL32	F	5'-TTACCGCTCGAGGTGCTTTCGGTGGTCTGC-3'	782
LipL32	R	5'-TGTTAACCCGGGTTACTTAGTCGCGTCAGA-3'	
LipL32	FF	5'-TGGATCTGTGATCAACTATTACG-3'	506
LipL32	RR	5'-CACTTCACCTGGTTTGTAGGTA-3'	
CollagenaseF		5'-TCGACAACAGTAAGCGTTAGC-3'	209
Collagenase R		5'-CGTGCAACGTAACCTCCATTAC-3'	

Table 2 PCR conditions

Primer names	Denaturing (°C)	Annealing (°C)	Elongation (°C)	# of Cycles
HPRT	94	62	68	40
TNF- $\alpha$	94	62	68	40
TGF- $\beta$	94	60	68	30
IL-10	94	60	72	35
IP-10	94	55	72	35
16S rRNA	94	55	72	30
LipL21	94	55	72	30
LipL32 (external round)	94	59	72	30
LipL32 (internal round)	94	55	72	30
Collagenase	94	55	72	40

#### *Microscopic agglutination test (MAT)*

MAT is the reference methods for detecting antibody to *Leptospira* which can be used for both human and animal sera. Sera were diluted 1:10 before mixing with *Leptospira interrogans* serovar Pyrogenes and agglutination was observed under a dark-field microscope. Sera that gave positive results were further diluted to obtain end point or antibody titer.

สถาบันวิทยบริการ  
จุฬาลงกรณ์มหาวิทยาลัย

## RESULTS

### *Kidney, Liver and lung pathologies*

Kidney, liver and lung pathologies were summarized in Table 3 and Table 4. Although these two groups of animals were injected with the same isolate of *Leptospira*, tissue pathologies observed were not similar. Pathologies in kidneys, livers and lungs of hamsters infected with virulent *Leptospira* were more severe than the avirulent group especially in kidneys and lungs.



สถาบันวิทยบริการ  
จุฬาลงกรณ์มหาวิทยาลัย



Table 3 Pathologies observed in kidney, liver and lung tissues of hamsters infected with avirulent *Leptospira*

(\* = days postinfection)

•	Liver	Lung	Kidney
3	Normal tissue morphology. Section of liver reveals normal architecture without evidence of inflammation.	Vascular congestion Section of lung reveals diffuse vascular congestion. No evidence of inflammation is present.	Normal tissue morphology. Section reveals normal renal tissue including both cortex and medulla. No evidence of inflammation is present.
3	Congestion with moderate hydropic degeneration. Section of liver reveals vascular and sinusoidal congestion with moderate hydropic degeneration of hepatocytes. No evidence of inflammation is present.	Vascular congestion with focal hemorrhage. Section of lung reveals diffuse vascular congestion with focal hemorrhage. No evidence of inflammation is present.	Normal tissue morphology Section reveals normal renal tissue including both cortex and medulla. No evidence of inflammation is present.
3	Congestion with moderate hydropic degeneration Section of liver reveals vascular and sinusoidal congestion with moderate hydropic degeneration of hepatocytes. No evidence of inflammation is present.	Vascular congestion Section reveals lung tissue showing diffuse vascular congestion. No evidence of inflammation is present.	Normal tissue morphology Section reveals normal renal tissue including both cortex and medulla. No evidence of inflammation is present.

•	Liver	Lung	Kidney
7	<p>Congestion with moderate hydropic degeneration</p> <p>Acute portal triaditis, mild</p> <p>Section of liver reveals vascular and sinusoidal congestion with moderate hydropic degeneration of hepatocytes. Focal mild acute inflammatory cell infiltration at portal triad is noted.</p>	<p>Section of lung reveals diffuse vascular congestion. No evidence of inflammation is present.</p>	<p>Normal tissue morphology</p> <p>Section reveals normal renal tissue including both cortex and medulla. No evidence of inflammation is present.</p>
7	<p>Congestion with moderate hydropic degeneration . Acute portal triaditis, mild</p> <p>Section of liver reveals vascular and sinusoidal congestion with moderate hydropic degeneration of hepatocytes. Focal mild acute inflammatory cell infiltration at portal triad is noted.</p>	<p>Vascular congestion with focal hemorrhage.</p> <p>Section of lung reveals diffuse vascular congestion with focal hemorrhage. No evidence of inflammation is present.</p>	<p>Normal tissue morphology</p> <p>Section reveals normal renal tissue including both cortex and medulla. No evidence of inflammation is present.</p>
7	<p>Congestion with moderate hydropic degeneration. Acute portal triaditis,mild</p> <p>Section of liver reveals vascular and sinusoidal congestion with moderate hydropic degeneration of hepatocytes. Focal mild acute inflammatory cell infiltration at portal triad is noted.</p>	<p>Vascular congestion</p> <p>Section reveals lung tissue showing diffuse vascular congestion. No evidence of inflammation is present.</p>	<p>Normal tissue morphology</p> <p>Section reveals normal renal tissue including both cortex and medulla. No evidence of inflammation is present.</p>

•	Liver	Lung	Kidney
14	Congestion with moderate hydropic degeneration . Acute portal triaditis,mild Section of liver reveals vascular and sinusoidal congestion with mild hydropic degeneration of hepatocytes. Focal mild acute and chronic inflammatory cell infiltration at portal triad is noted.	Vascular congestion with hemorrhage. Section of lung reveals diffuse vascular congestion with diffuse pulmonary hemorrhage. No evidence of inflammation is present.	Normal tissue morphology. Section reveals normal renal tissue including both cortex and medulla. No evidence of inflammation is present.
14	Tissue was missing during staining process.	Vascular congestion Section reveals lung tissue showing diffuse vascular congestion. No evidence of inflammation is present.	Normal tissue morphology Section reveals normal renal tissue including both cortex and medulla. No evidence of inflammation is present.
14	Congestion with moderate hydropic degeneration. Section of liver reveals vascular and sinusoidal congestion with moderate hydropic degeneration of hepatocytes. No evidence of inflammation is present.	Vascular congestion Section reveals a small piece of lung and connective tissue. The lung tissue reveals diffuse vascular congestion. No spleen included.	Normal tissue morphology Section reveals normal renal tissue including both cortex and medulla. No evidence of inflammation is present.

•	Liver	Lung	Kidney
21	Congestion with moderate hydropic degeneration. Chronic portal triaditis, mild Section of liver reveals vascular and sinusoidal congestion with moderate hydropic degeneration of hepatocytes. Focal mild chronic inflammatory cell infiltration at portal triad is noted.	Vascular congestion Section of lung reveals diffuse vascular congestion. No evidence of inflammation is present.	Normal tissue morphology Section reveals normal renal tissue including both cortex and medulla. No evidence of inflammation is present.
21	Section of liver reveals vascular and sinusoidal congestion with moderate hydropic degeneration of hepatocytes. No evidence of inflammation is present.	Vascular congestion Section of lung reveals diffuse vascular congestion. No evidence of inflammation is present.	Normal tissue morphology Section reveals normal renal tissue including both cortex and medulla. No evidence of inflammation is present.
21	Congestion with moderate hydropic degeneration. Chronic portal triaditis, moderate. Section of liver reveals vascular and sinusoidal congestion with moderate hydropic degeneration of hepatocytes. Focal chronic inflammatory cell infiltration at portal triad is noted.	Tissue was missing during staining process.	Vascular congestion Section reveals renal tissue including both cortex and medulla. Diffuse vascular congestion is noted. No evidence of inflammation is present.

Table 4 Pathologies observed in kidney, liver and lung tissues of hamsters infected with virulent *Leptospira*

(\* = days postinfection)

•	Liver	Lung	Kidney
3	<p>Presence of swelling of hepatocytes at centrilobular areas, mild.</p> <p>Section of liver reveals mild swelling of hepatocytes at centrilobular areas. No inflammatory cell infiltration is detected.</p>	<p><b>Atelectasis, severe</b></p> <p>The section shows scattered atelectasis. No inflammatory cell infiltration is present.</p>	<p>Mild acute tubular cell injury.</p> <p>Section reveals mild swelling of proximal renal tubular epithelial cells with congestion of vessels in the parenchyma and glomeruli.</p>
3	<p>Moderate swelling of hepatocytes at centrilobular areas with presence of few neutrophilic infiltration in sinusoids.</p> <p>Section of liver reveals moderate swelling of hepatocytes at centrilobular areas. Few scattered neutrophilic infiltration in sinusoids are detected.</p>	<p><b>Atelectasis, mild</b></p> <p>The section shows focal atelectasis. No inflammatory cell is present.</p>	<p>Mild acute tubular cell injury.</p> <p>Section reveals mild swelling of proximal renal tubular epithelial cells with congestion of vessels in the parenchyma and glomeruli.</p>
3	<p>Moderate swelling of hepatocytes at centrilobular areas and some hepatic lobules with presence of few lymphocytic infiltration at some portal tracts.</p> <p>Section of liver reveals moderate of swelling of hepatocytes at centrilobular areas and some hepatic lobules. Few lymphocytic infiltration at some portal tracts are detected.</p>	<p><b>Atelectasis, mild</b></p> <p>The section shows focal atelectasis. No inflammatory cell is present.</p>	<p>Mild acute tubular cell injury.</p> <p>Section shows renal tubular cell swelling with focal tubular epithelial necrosis. The glomeruli are unremarkable.</p>

•	Liver	Lung	Kidney
3	<p>Moderate swelling of hepatocytes at centrilobular areas and some hepatic lobules with presence of few lymphocytic infiltration at some portal tracts. Section of liver reveals moderate of swelling of hepatocytes at centrilobular areas and some hepatic lobules. Few lymphocytic infiltration at some portal tracts are detected.</p>	<p><b>Unremarkable</b> The section shows unremarkable change.</p>	<p>Moderate acute tubular necrosis. Section reveals generalized tubular epithelial swelling with scattered tubular cell necrosis. The glomeruli are unremarkable.</p>
5	<p>Congestion. Section shows dilated hepatic sinusoids which contain red blood cells together with congested central veins and hepatic veins. There are mild lymphocytic infiltrate at some portal tracts areas.</p>	<p><b>Pneumonia, mild</b> <b>Hemorrhage, mild</b> The section shows focal acute inflammatory cell infiltration and hemorrhage.</p>	<p>Moderate acute tubular necrosis. Section shows generalized tubular epithelial swelling with scattered tubular cell necrosis. There are protein casts in some tubular lumens. The glomeruli are unremarkable.</p>
5	<p>Congestion. Section shows dilated hepatic sinusoids which contain red blood cells together with congested central veins and hepatic veins. There are mild lymphocytic infiltrate at some portal tracts areas.</p>	<p><b>Hemorrhage, severe</b> The section shows generalized hemorrhage. No inflammatory cell infiltration is seen.</p>	<p>Severe acute tubular necrosis. Section shows generalized tubular epithelial swelling with scattered tubular cell necrosis. There are protein casts in some tubular lumens. The glomeruli are unremarkable.</p>
5	<p>Moderate hepatocytic swelling with congestion. Section shows moderate ballooning degeneration of hepatocytes mostly at zone 3 area together with congestion of hepatic sinusoids, central veins, and hepatic veins.</p>	<p><b>Unremarkable</b> The section shows unremarkable change.</p>	<p>Mild acute tubular cell injury. Section reveals mild swelling of proximal renal tubular epithelial cells with congestion of vessels in the parenchyma and glomeruli.</p>

•	Liver	Lung	Kidney
5	<p>Congestion.</p> <p>Section shows dilated hepatic sinusoids which contain red blood cells together with congested central veins and hepatic veins. There are mild lymphocytic infiltrate at some portal tracts areas.</p>	<p>Pneumonia, severe</p> <p>The section shows scattered acute inflammation throughout pulmonic parenchyma.</p>	<p>Moderate acute tubular cell injury.</p> <p>Section reveals feathery degeneration of proximal renal tubular cells together with swelling of distal renal tubular epithelial cells. Some tubules contains eosinophilic protein casts.</p>
7	<p>Focal hepatocytic swelling with congestion.</p> <p>Section reveals focal area of ballooning degeneration of hepatocytes together with congestion of hepatic sinusoids, central veins, and hepatic veins. There are few scattered lymphocytes infiltrate in the sinusoids</p>	<p>Atelectasis, mild</p> <p>Hemorrhage, mild</p> <p>The section shows focal atelectasis and hemorrhage. No inflammatory cell infiltration is seen.</p>	<p>Early renal necrosis.</p> <p>Section discloses generalized karyorexis of renal epithelium with shrinkage of the renal tubules and generalized necrosis of glomerular cells.</p>
7	<p>Generalized hepatocytic swelling with few scattered liver cell necrosis in hepatic lobules.</p> <p>Section shows generalized ballooning degeneration of hepatocytes and few scattered liver cell necrosis in hepatic lobules together with congestion of hepatic sinusoids, central veins, and hepatic veins.</p> <p>There are few lymphocytes infiltrate in the sinusoids and some portal tracts.</p>	<p>Pneumonia, severe,</p> <p>Hemorrhage, mild</p> <p>The section shows scattered acute inflammatory cell infiltration throughout pulmonic parenchyma. Focal hemorrhage is detected.</p>	<p>Moderate acute tubular necrosis.</p> <p>Section reveals generalized tubular epithelial swelling with scattered tubular cell necrosis. The glomeruli are unremarkable.</p>

•	Liver	Lung	Kidney
7	<p><b>Congestion</b></p> <p>Section shows dilated hepatic sinusoids, central veins. And hepatic veins, containing numerous red cells. There are mild lymphocytes infiltrate at some portal tracts.</p>	<p><b>Pneumonia, severe</b></p> <p>The section shows scattered acute inflammatory cell infiltration throughout lung parenchyma.</p>	<p><b>Mild acute tubular necrosis.</b></p> <p>Section shows renal tubular cell swelling with focal tubular epithelial necrosis. The glomeruli are unremarkable.</p>
7	<p><b>Generalized hepatocytic swelling with congestion.</b></p> <p>Section shows generalized hepatic swelling and congestion of sinusoids, central veins, and hepatic veins. No inflammatory cell is detected..</p>	<p><b>Hemorrhage, severe</b></p> <p>The section shows generalized pulmonic parenchymal hemorrhage. No inflammatory cell infiltration is noted.</p>	<p><b>Mild acute tubular necrosis.</b></p> <p>Section shows renal tubular cell swelling with focal tubular epithelial necrosis. The glomeruli are unremarkable.</p>



### *TNF- $\alpha$ , TGF- $\beta$ , IL-10, and IP-10 mRNA expression*

HPRT mRNA expression in all tissues was detected to demonstrate that successful RNA extraction and reverse transcription were obtained as shown in Figure 1 for tissues from non-infected hamsters, Figures 2-4 from hamsters infected with virulent *Leptospira* and Figures 21-23 from hamsters infected with avirulent *Leptospira*. HPRT mRNA expression was detected in all tissues tested.

TNF- $\alpha$  and TGF- $\beta$  expression was detected in tissues from non-infected hamsters, hamsters infected with virulent or avirulent *Leptospira* (Figures 5, 6-8 and 24-26 for TNF- $\alpha$  and Figures 9, 10-12 and 27-29).

IL-10 expression was undetectable in tissues from non-infected hamsters and from hamsters infected with avirulent *Leptospira* (Figures 10 and 30-32). However, IL-10 expression was detected in kidney, liver and lung tissues from hamsters infected with virulent hamsters although the level of expression was relatively low (Figures 14-16).

In non-infected hamsters, IP-10 expression slightly expressed in kidneys and the expression seemed higher in lung tissues. Only one out of 4 liver tissues from non-infected hamsters showed IP-10 expression (Figure 17). IP-10 expression was shown in kidney and tissues of hamsters infected with virulent *Leptospira* (Figures 18 and 19). However, the expression of IP-10 was undetectable in livers from the same group (Figure 20). The expression of IP-10 was undetectable in kidney and liver tissues from hamsters infected with avirulent *Leptospira* (Figures 33 and 34). Similar to non-infected and virulent group, IP-10 expression could be demonstrated in lung tissues (Figure 35).

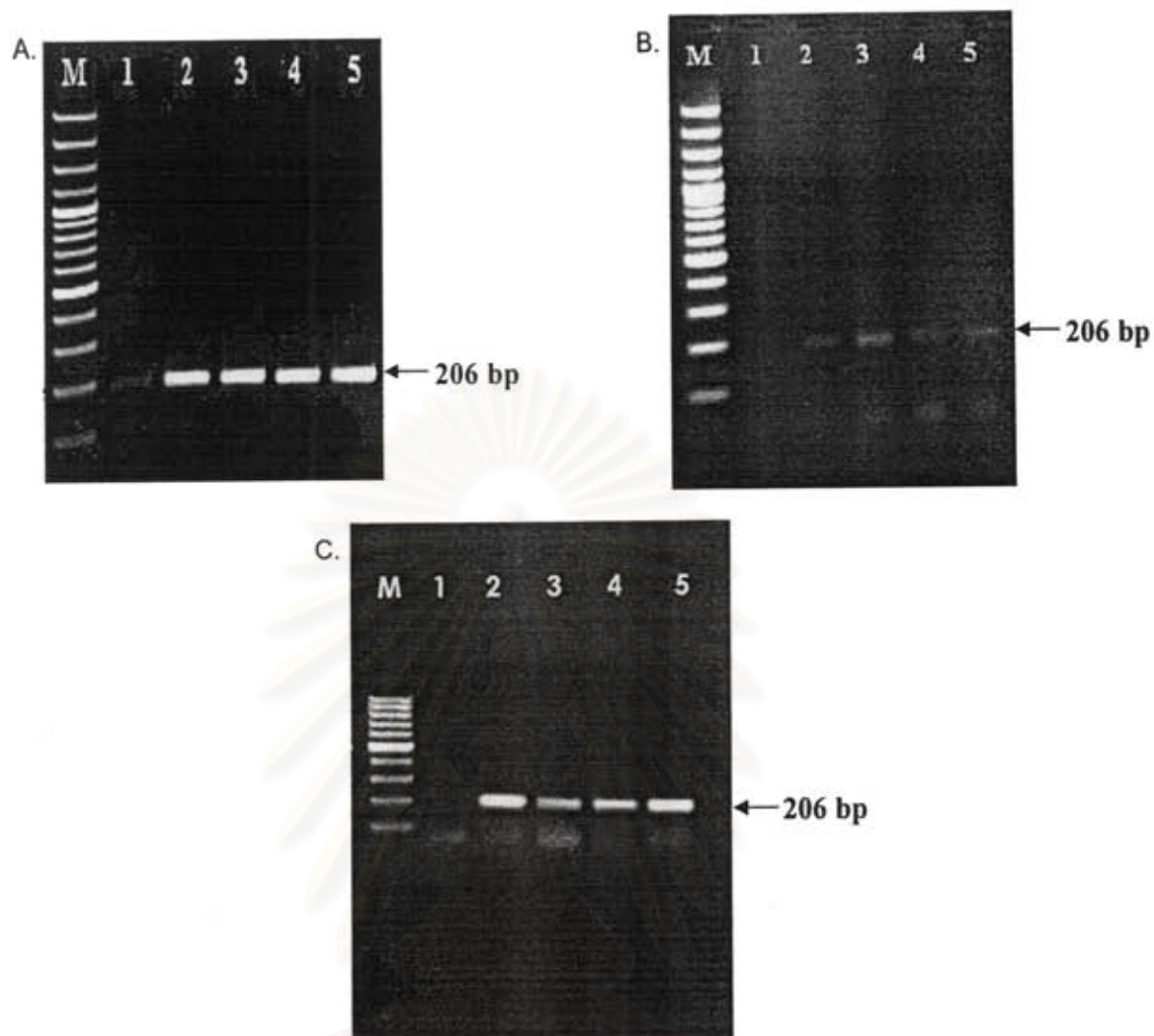


Figure 1. HPRT expression in kidneys (A), livers (B) and lungs.(C) of non-infected hamsters. The results were from four hamsters (Lanes 2-5). M = 100 bp marker; Lane 1 = negative control.

สถาบันวิทยบริการ  
จุฬาลงกรณ์มหาวิทยาลัย

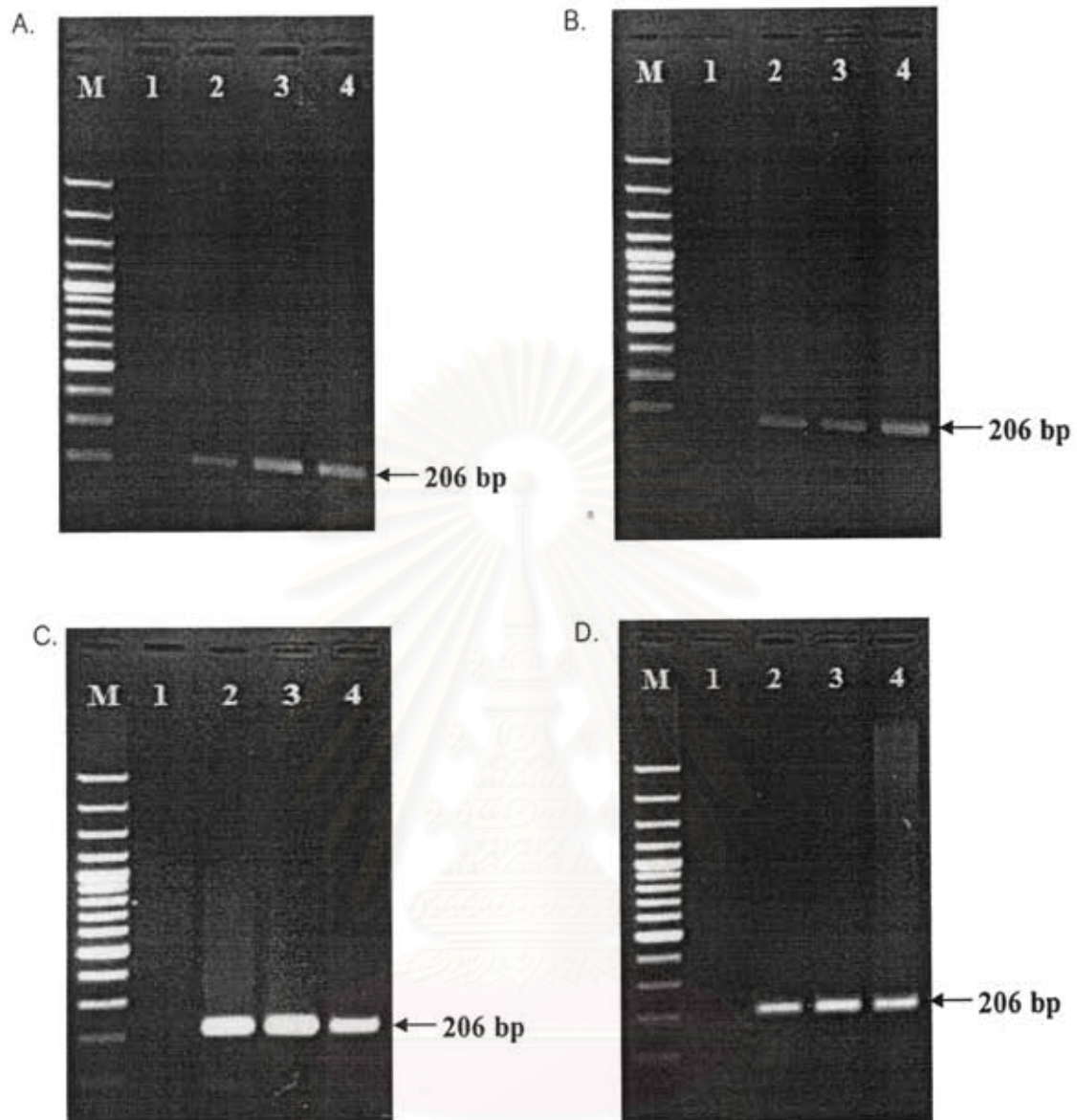


Figure 2. HPRT expression in kidneys from hamsters infected with virulent *Leptospira* at 3, 5, 7 days post infection (Lanes 2,3 and 4, respectively). The results shown were from 12 hamsters (four for each timepoint). M = 100 bp-marker; Lane 1 = negative control.

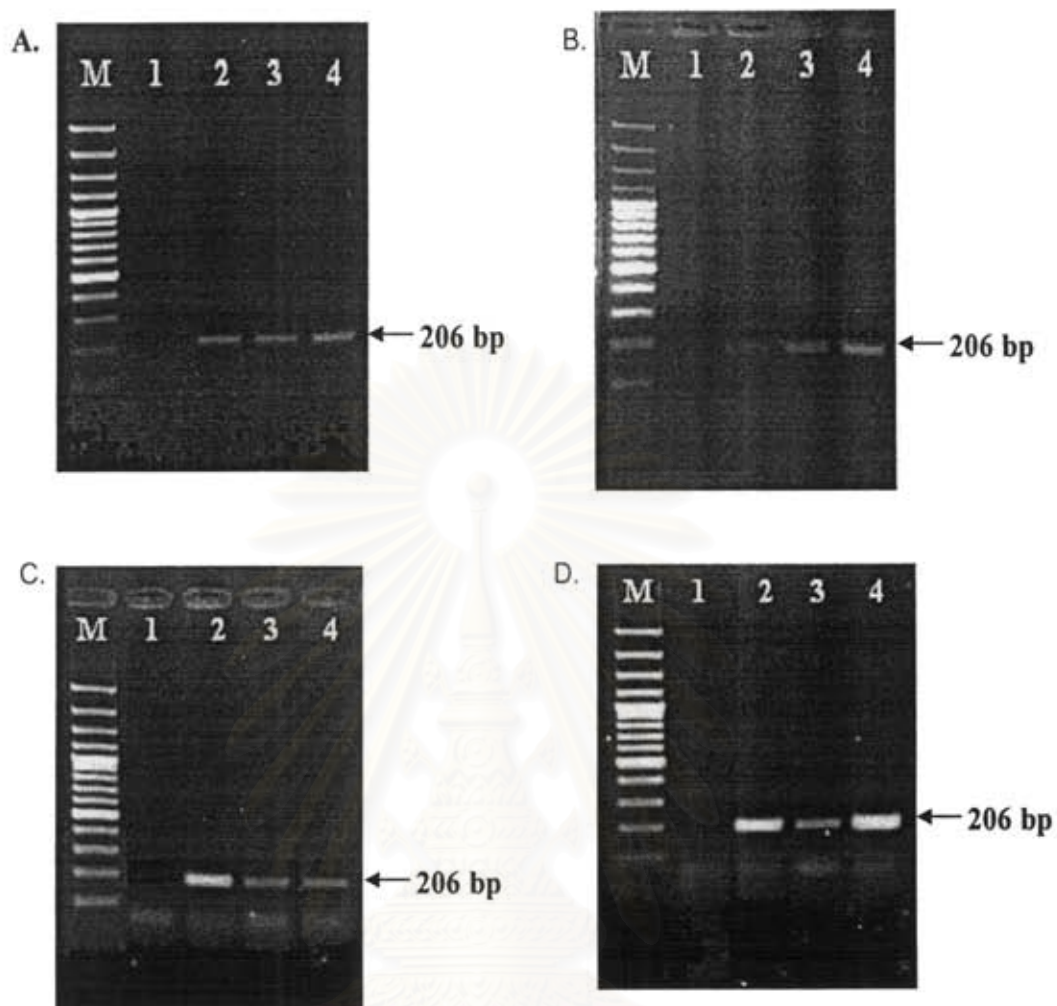


Figure 3. HPRT expression in livers from hamsters infected with virulent *Leptospira* at 3, 5, 7 days post infection (Lanes 2,3 and 4, respectively). The results shown were from 12 hamsters (four for each timepoint). M = 100 bp-marker; Lane 1 = negative control.

สถาบันวิทยบริการ  
จุฬาลงกรณ์มหาวิทยาลัย

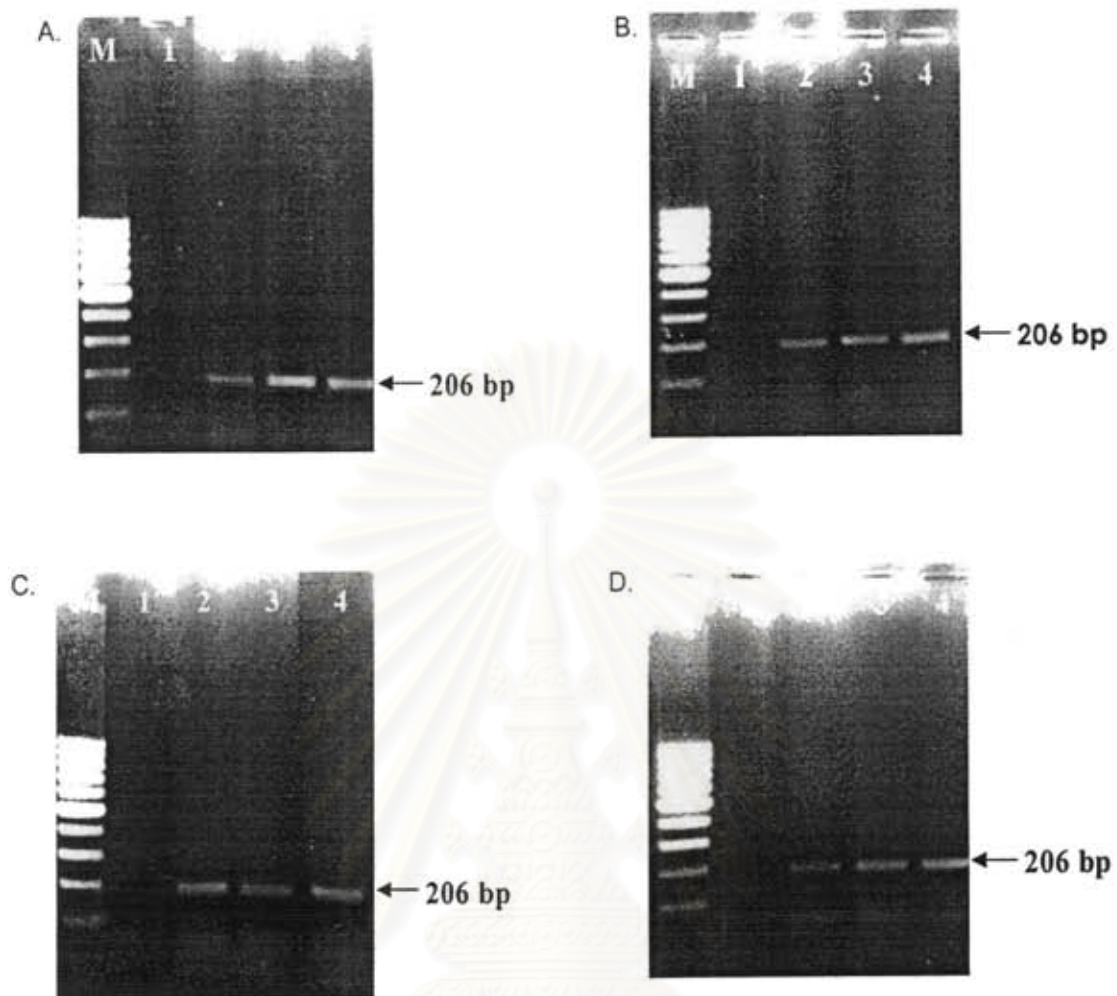


Figure 4. HPRT expression in lungs from hamsters infected with virulent *Leptospira* at 3, 5, 7 days post infection (Lanes 2,3 and 4, respectively). The results shown were from 12 hamsters (four for each timepoint). M : 100 bp-marker; Lane 1 : negative control.

สถาบันวิทยบริการ  
จุฬาลงกรณ์มหาวิทยาลัย

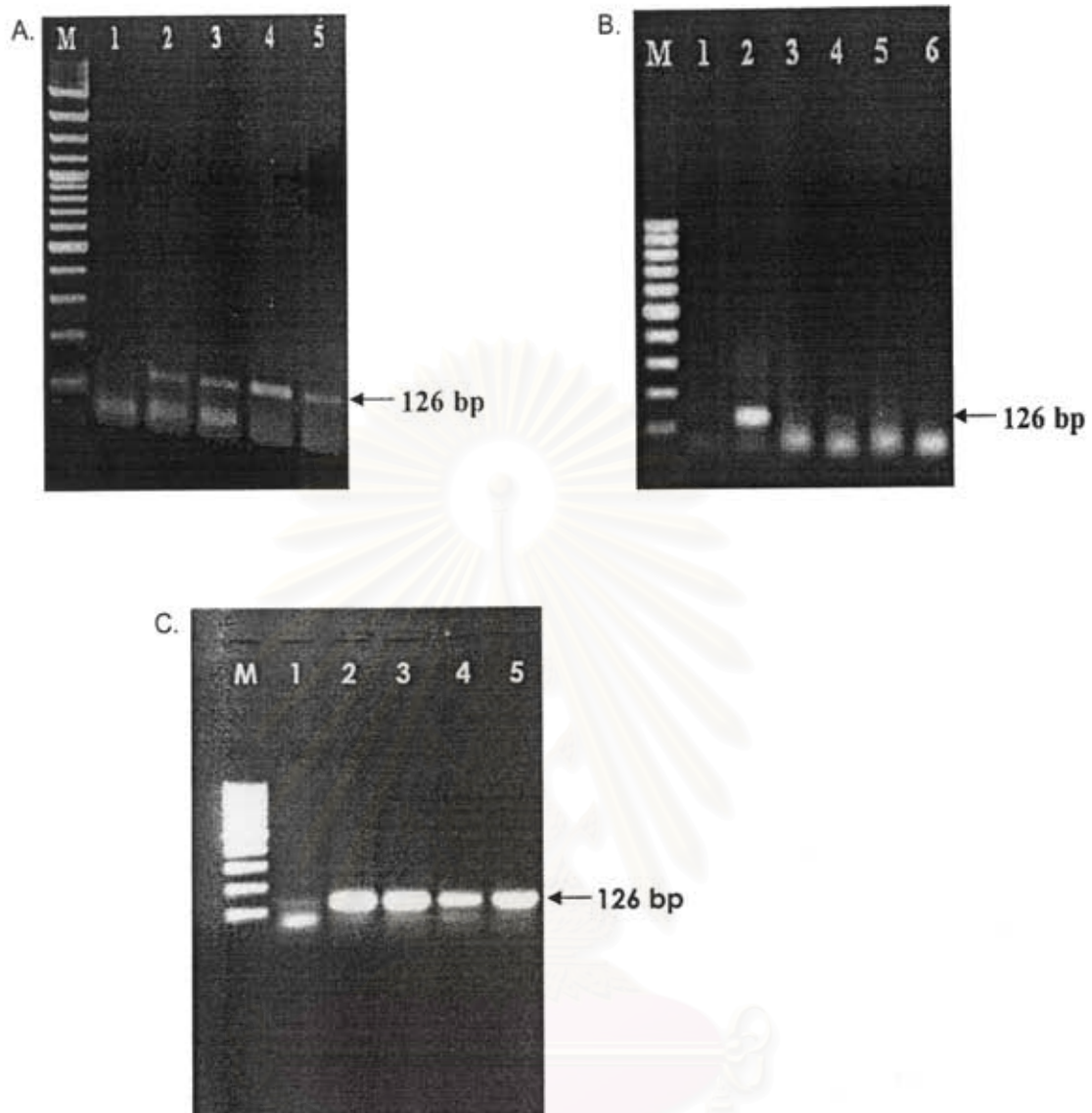


Figure 5. TNF- $\alpha$  expression in kidneys (A), livers (B) and lungs.(C) of non-infected hamsters. The results were from four hamsters (Lanes 2-5). M =100 bp marker. Lane 1 = negative control.

จุฬาลงกรณ์มหาวิทยาลัย

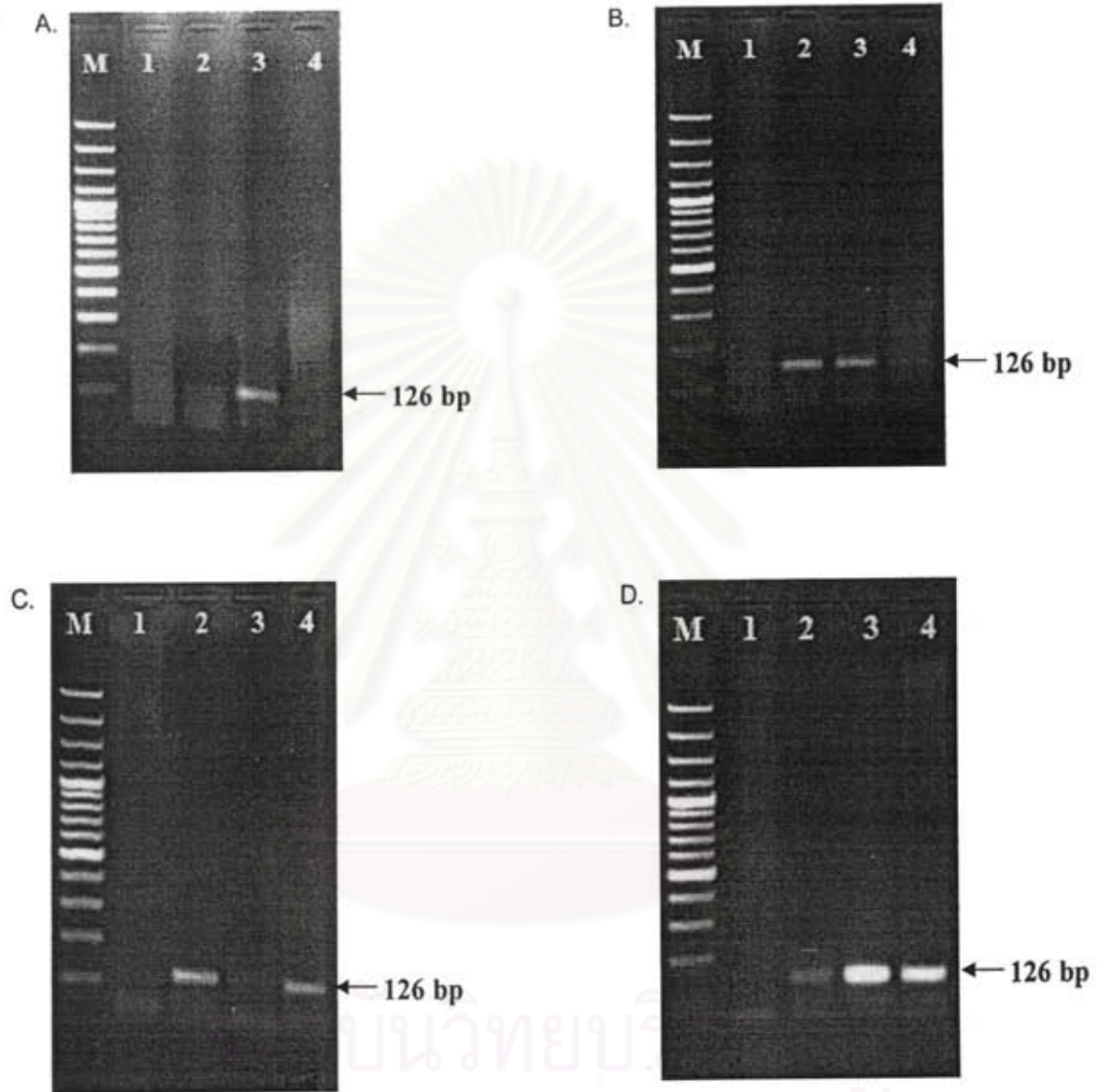


Figure 6. TNF- $\alpha$  expression in kidneys from hamsters infected with virulent *Leptospira* at 3, 5, 7 days post infection (Lanes 2-4, respectively). Four hamsters were used for each timepoint (A-D). M = 100 bp- marker; Lane 1 : negative control.

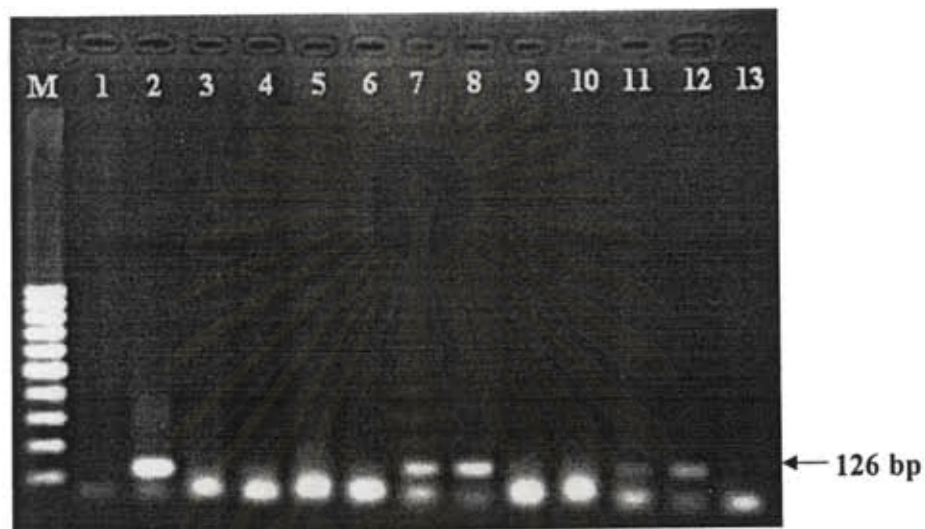

Figure 7. TNF- $\alpha$  expression in kidneys from hamsters infected with virulent *Leptospira* at 3, 5, 7 days post infection. Four hamsters were used for each timepoint. M = 100 bp- marker; Lane 1 : negative control. Lanes 2, 5, 8, 11 = 3 days postinfection; Lanes 3, 6, 9, 12 = 5 days postinfection; Lanes 4, 7, 10, 13 = 7 days postinfection.

สถาบันวิทยบริการ  
จุฬาลงกรณ์มหาวิทยาลัย



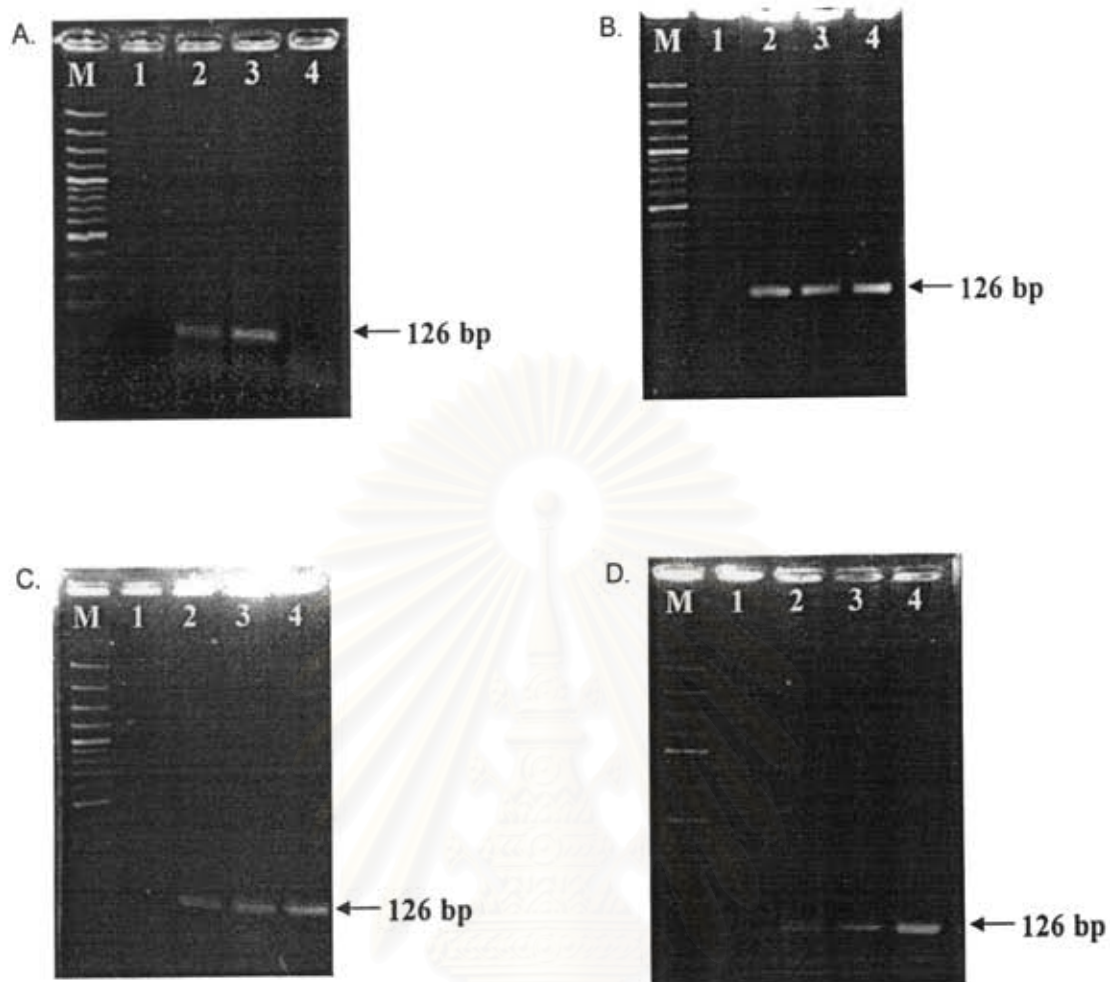


Figure 8. TNF- $\alpha$  expression in lungs from hamsters infected with virulent *Leptospira* at 3, 5, 7 days post infection (Lanes 2, 3 and 4, respectively). M = 100 bp-marker; Lane 1 = negative control.

สถาบันวิทยบริการ  
จุฬาลงกรณ์มหาวิทยาลัย

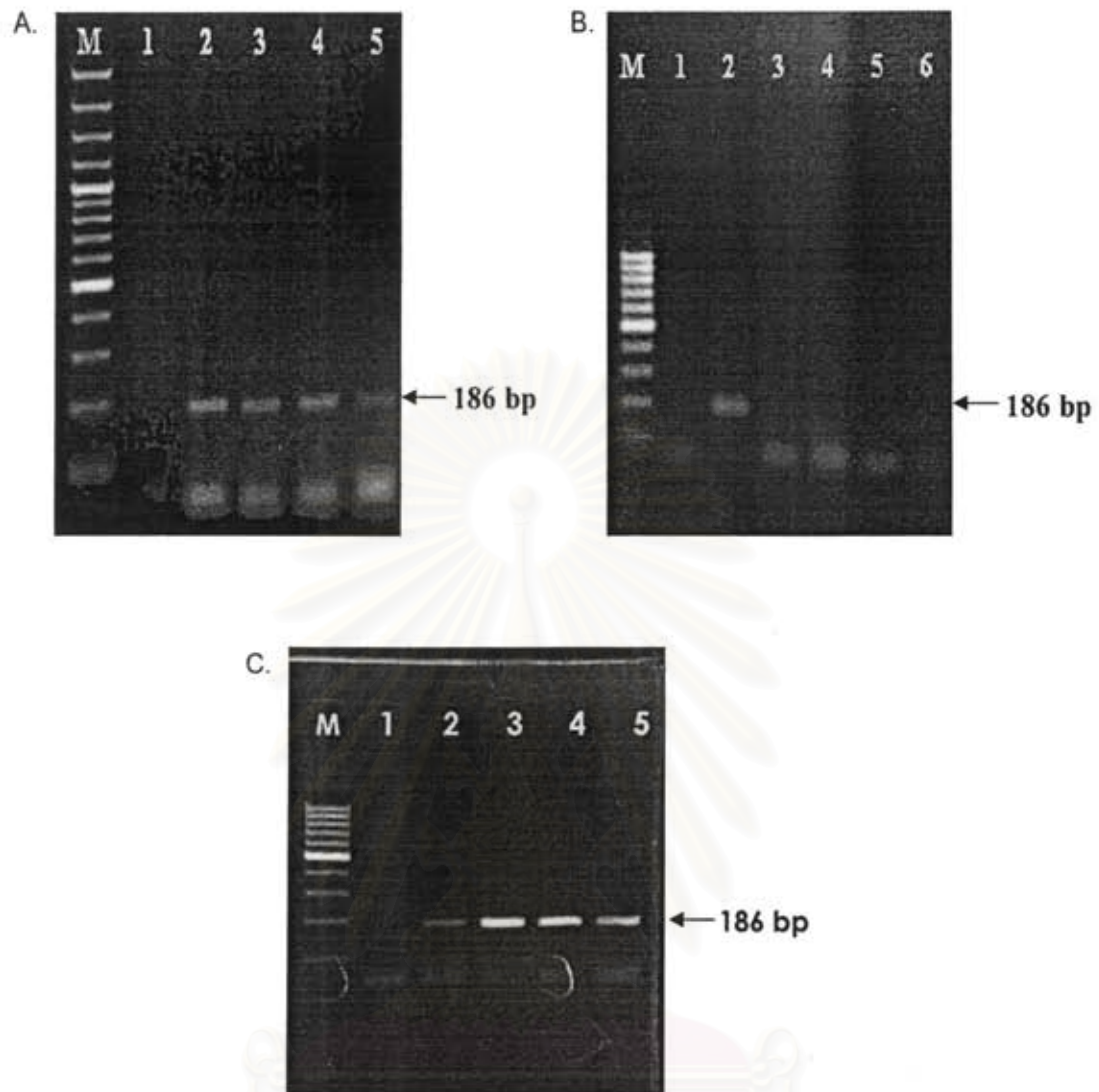


Figure 9. TGF- $\beta$  expression in kidneys (A), livers (B) and lungs.(C) of non-infected hamsters. The results were from four hamsters (Lanes 2-5). M =100 bp marker. Lane 1 = negative control.

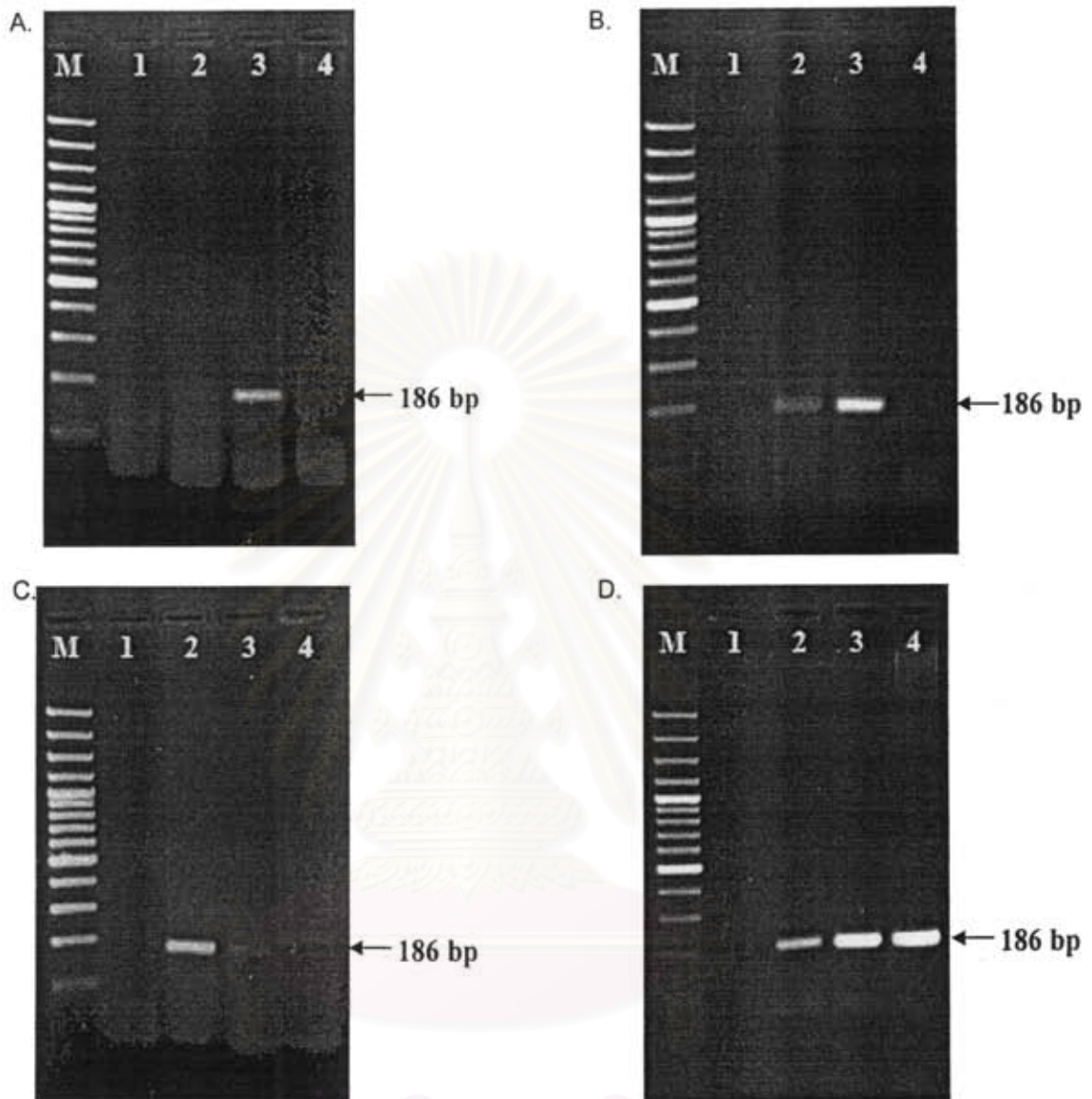


Figure 10. TGF- $\beta$  expression in kidneys from hamsters infected with virulent *Leptospira* at 3, 5, 7 days post infection (Lanes 2-4, respectively). Four hamsters were used for each timepoint (A-D). M= 100 bp-marker; Lane 1 = negative control.

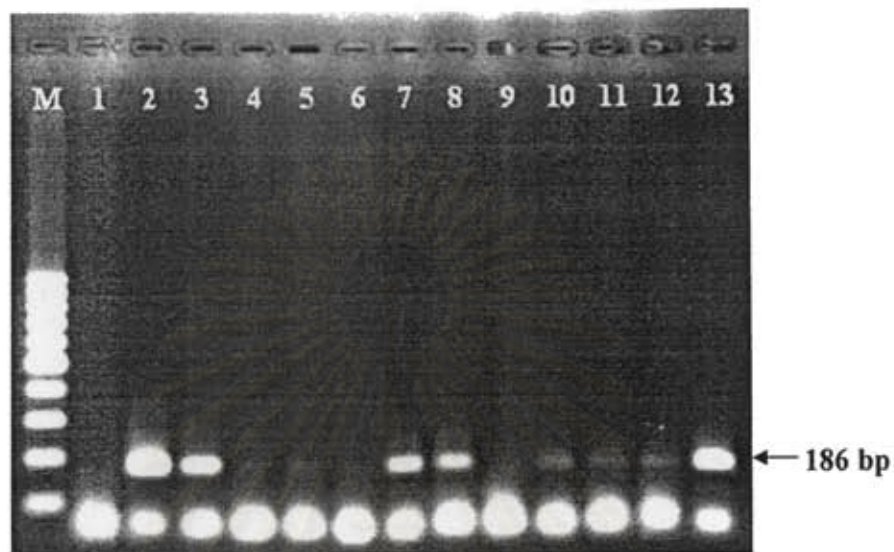


Figure 11. TGF- $\beta$  expression in livers from hamsters infected with virulent *Leptospira* at 3, 5, 7 days post infection. Four hamsters were used for each timepoint. M = 100 bp- marker; Lane 1 : negative control. Lanes 2, 5, 8, 11 = 3 days postinfection; Lanes 3, 6, 9, 12 = 5 days postinfection; Lanes 4, 7, 10, 13 = 7 days postinfection.

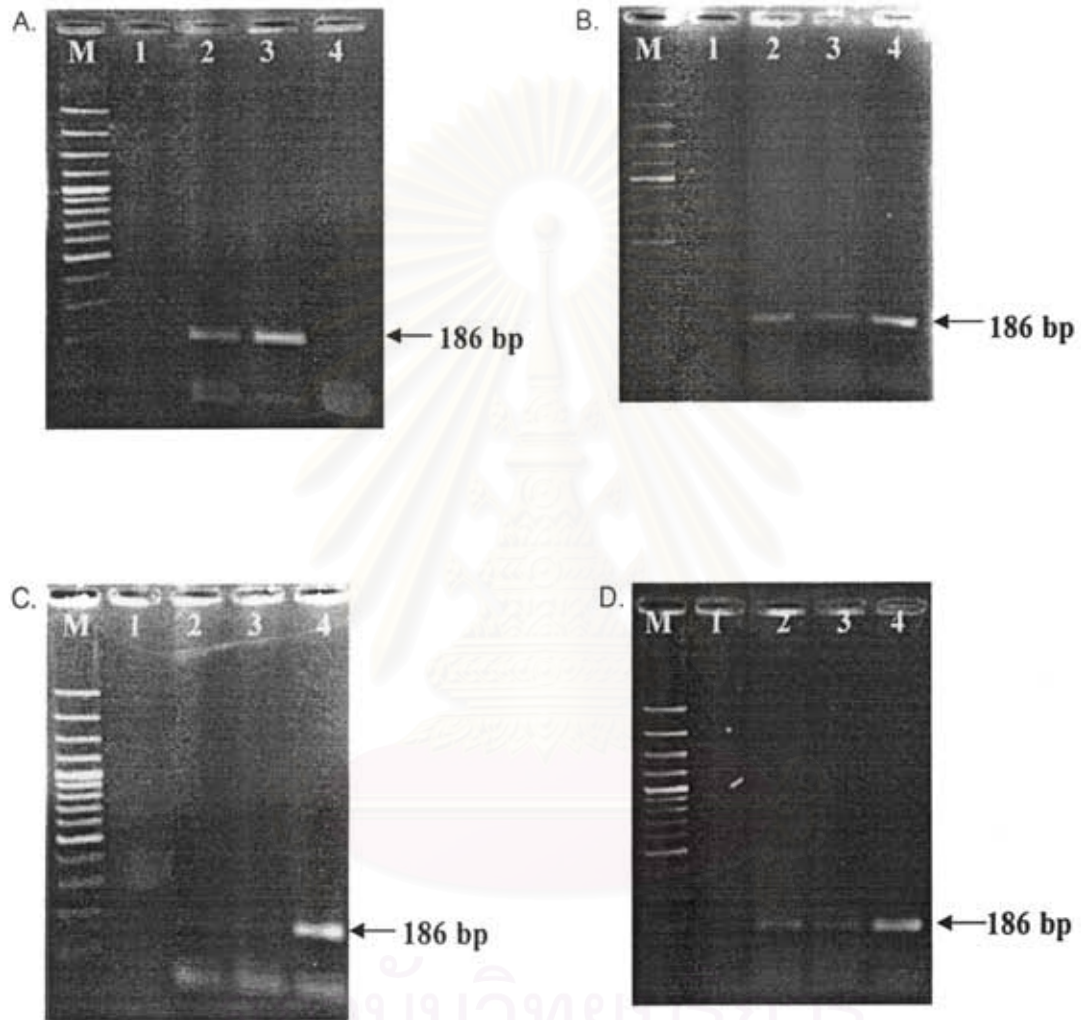


Figure 12. TGF- $\beta$  expression in lungs of hamsters infected with virulent leptospira at 3, 5, 7 days post infection (Lanes 2-4, respectively). Four hamsters were used for each timepoint (A-D). M = 100 bp-marker; Lane 1 = negative control.




Figure 13. IL-10 expression in kidneys (A), livers (B) and lungs (C) of non-infected hamsters. The results were from four hamsters (Lanes 3-6). M = 100 bp marker. Lane 1 = negative control; Lane 2 = positive control.

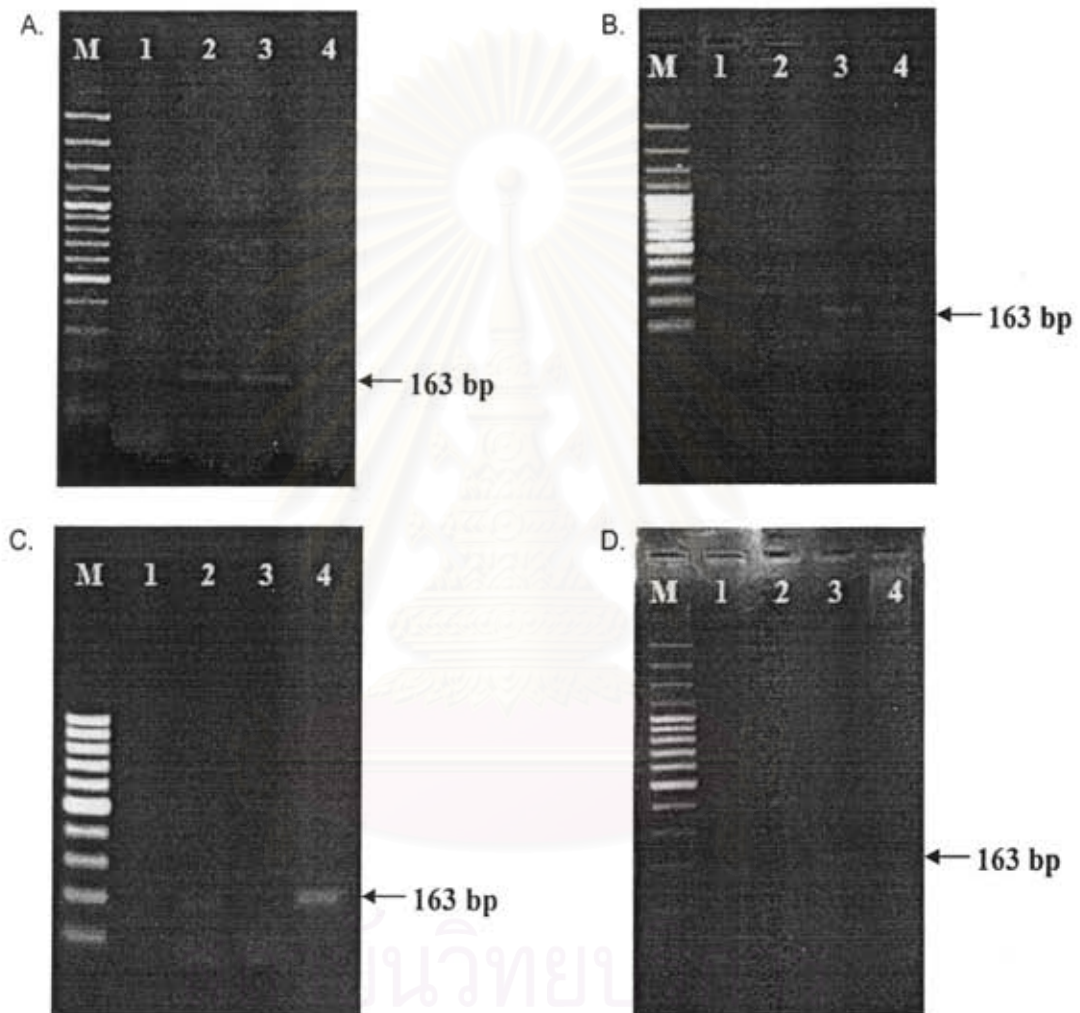


Figure 14. IL-10 expression in kidneys from hamsters infected with virulent *Leptospira* at 3, 5, 7 days post infection (Lanes 2-4, respectively). Four hamsters were used for each timepoint (A-D). M= 100 bp-marker; Lane 1 = negative control.



Figure 15. IL-10 expression in livers from hamsters infected with virulent *Leptospira* at 3, 5, 7 days post infection. Four hamsters were used for each timepoint. M = 100 bp- marker; Lane 1 : negative control; Lane 2 = positive control; Lanes 3, 6, 9,12 = 3 days postinfection; Lanes 4, 7, 10, 13 = 5 days postinfection; Lanes 5, 8,11, 14 = 7 days postinfection.

สถาบันวิทยบริการ  
จุฬาลงกรณ์มหาวิทยาลัย



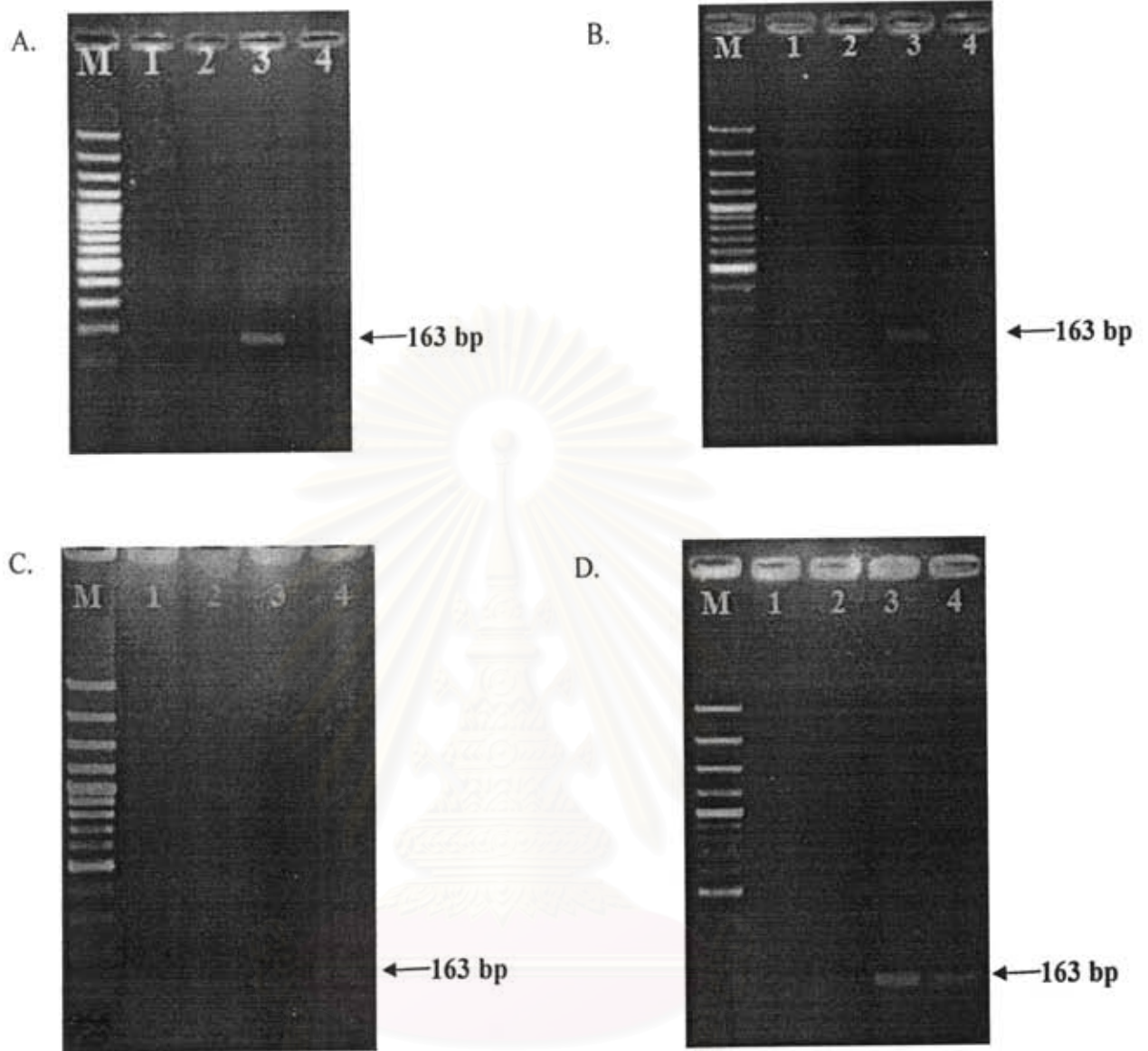


Figure 16. IL-10 expression in lungs from hamsters infected with virulent *Leptospira* at 3, 5, 7 days post infection (Lanes 2, 3 and 4 respectively). Four hamsters were used for each timepoint (A-D) M = 100-bp marker; Lane 1 = negative control.

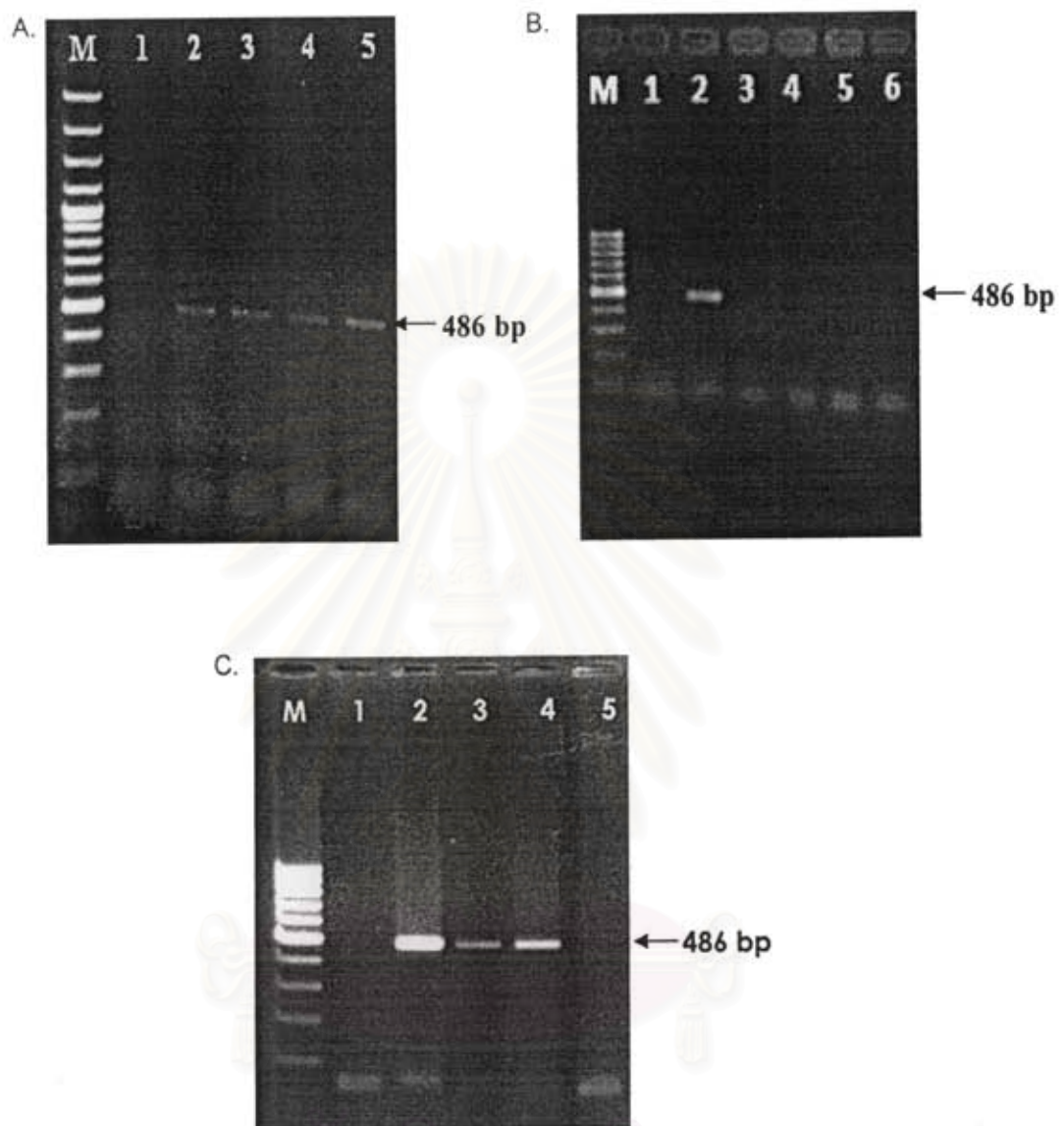


Figure 17. IP-10 expression in kidneys (A), livers (B) and lungs (C) of non-infected hamsters. The results were from four hamsters (Lanes 2-5). M = 100 bp-marker. Lane 1 = negative control.

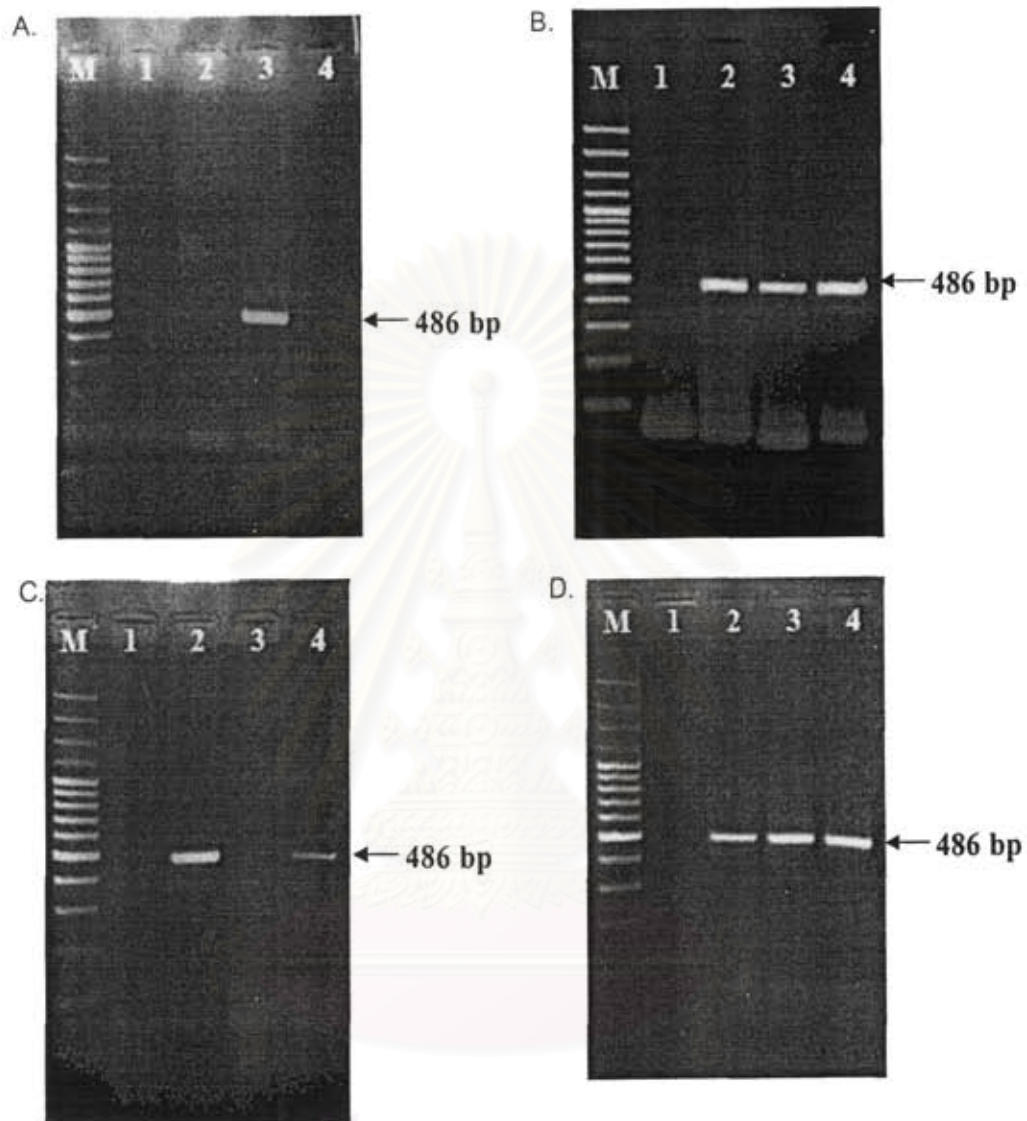


Figure 18. IP-10 expression in kidneys from hamsters infected with virulent *Leptospira* at 3, 5, 7 days post infection Lanes 2-4, respectively. Four hamsters were used for each timepoint (A-D). M= 100 bp-marker; Lane 1 = negative control.

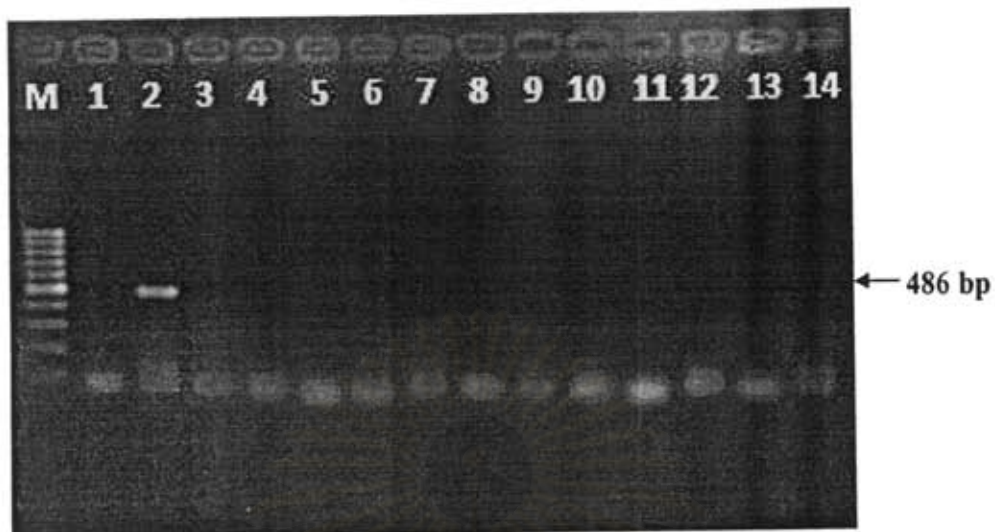


Figure 19. IP-10 in livers from hamsters infected with virulent *Leptospira* at 3, 5, 7 days post infection. Four hamsters were used for each timepoint. M = 100 bp- marker; Lane 1 : negative control; Lane 2 = positive control; Lanes 3, 6, 9,12 = 3 days postinfection; Lanes 4, 7, 10, 13 = 5 days postinfection; Lanes 5, 8,11, 14 = 7 days postinfection

สถาบันวิทยบริการ  
จุฬาลงกรณ์มหาวิทยาลัย

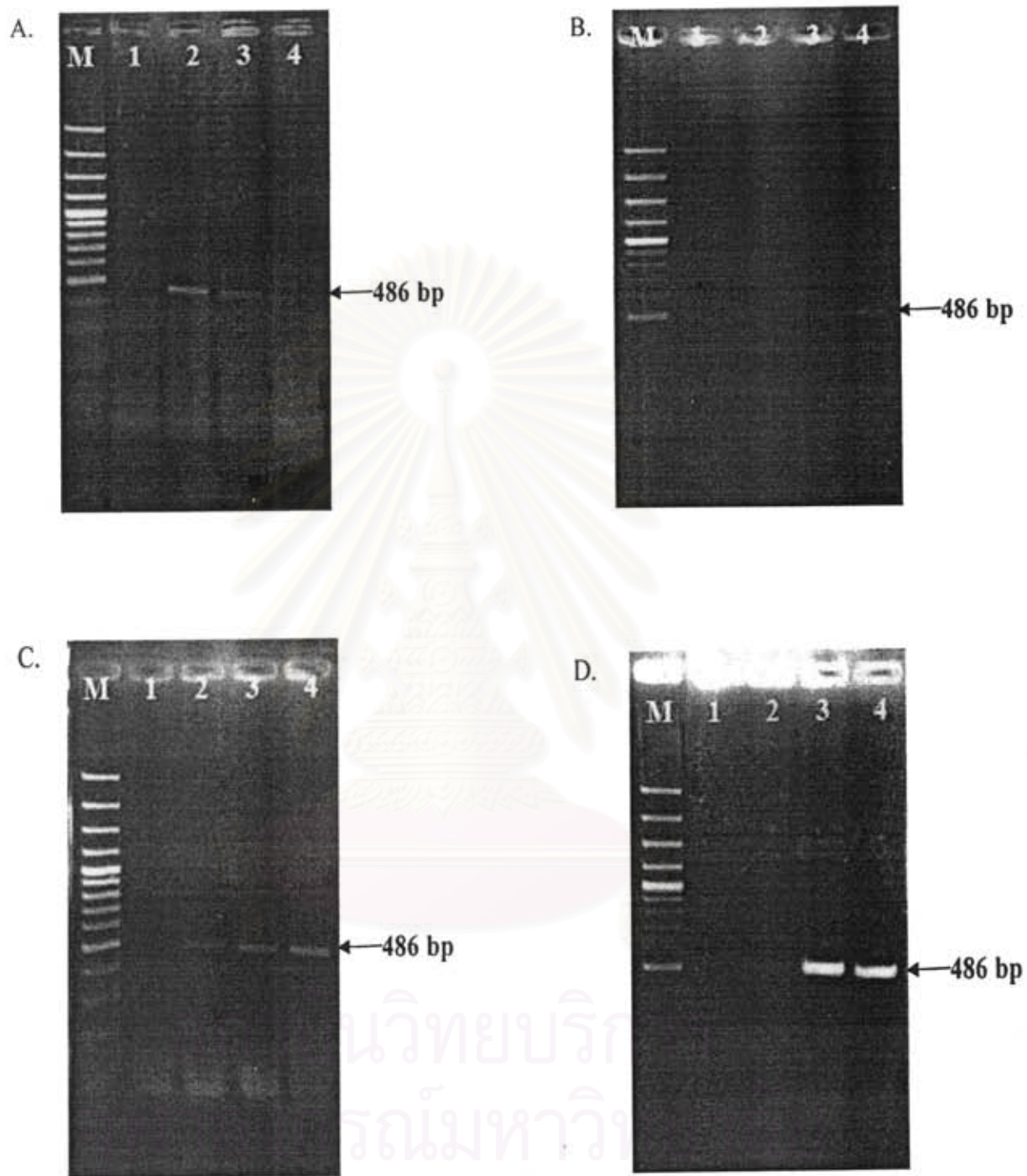


Figure 20. IP-10 expression in lungs from hamsters infected with virulent *Leptospira* at 3, 5, 7 days post infection (Lanes 2, 3 and 4 respectively). Four hamsters were used for each timepoint (A-D) M = 100-bp marker; Lane 1 = negative control.

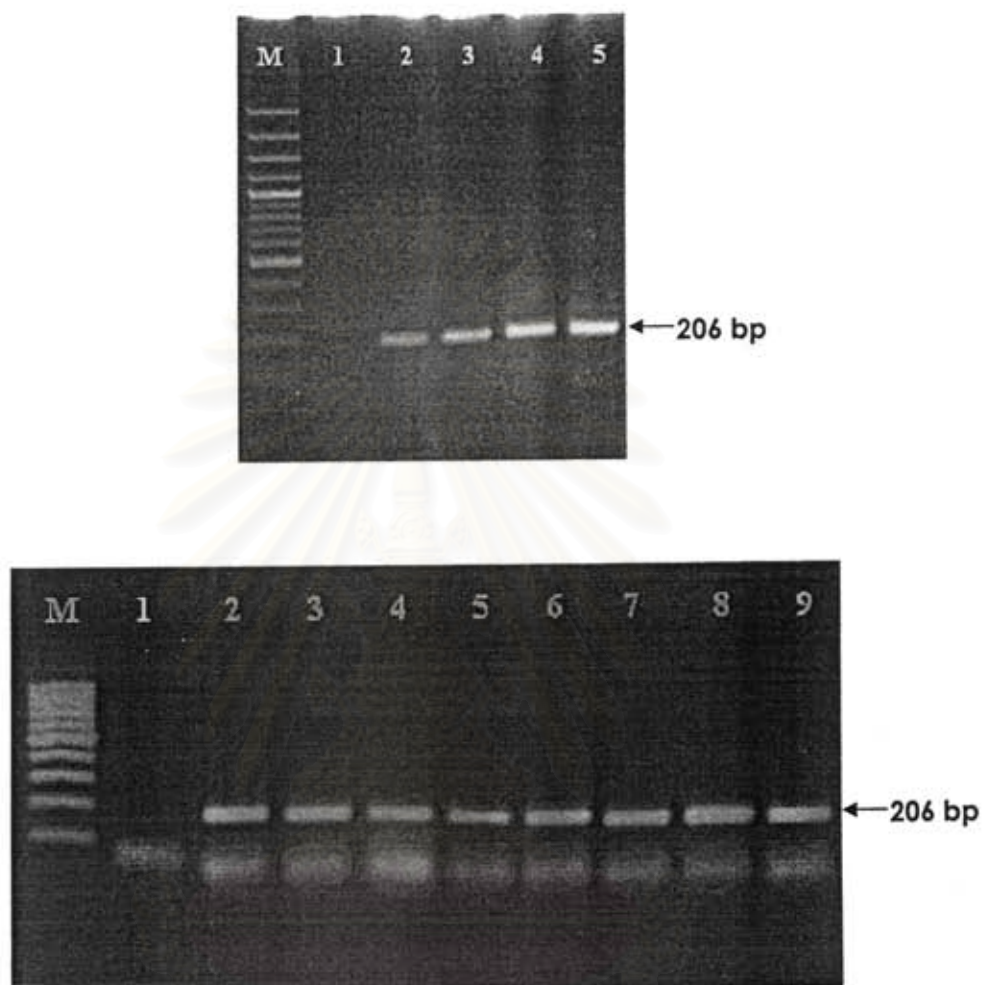


Figure 21. HPRT expression in kidneys from hamsters infected with avirulent *Leptospira* at day 3, 7, 14, 21 postinfection. Three hamsters were used for each timepoint. Lane M : marker; Lane 1: negative control. Top figure : Lanes 2,3,4, and 5 were from 3,7,14, and 21 days postinfection, respectively. Bottom figure: Lanes 2, 6 were from 3 days postinfection ; Lanes 3, 7 from 7 days; Lanes 4, 8 from 14 days; Lanes 5, 9 from 21 days postinfection.

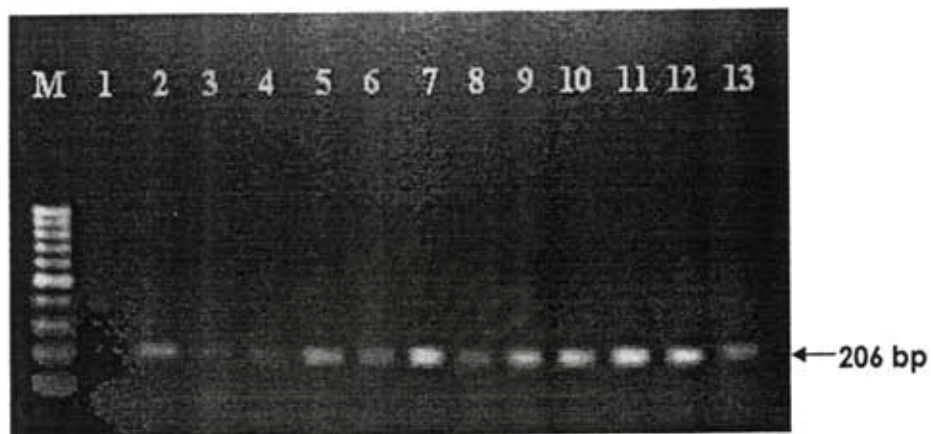


Figure 22. HPRT expression in livers from hamsters infected with avirulent hamsters. Lane M = 100 bp-marker; Lane 1: negative control; Lane 2, 6,10 were from 3 days postinfection; Lanes 3, 7, 11 from 7 days; Lanes 4, 8, 12 from 14 days; Lanes 5, 9, 13 were from 21 days postinfection.

สถาบันวิทยบริการ  
จุฬาลงกรณ์มหาวิทยาลัย

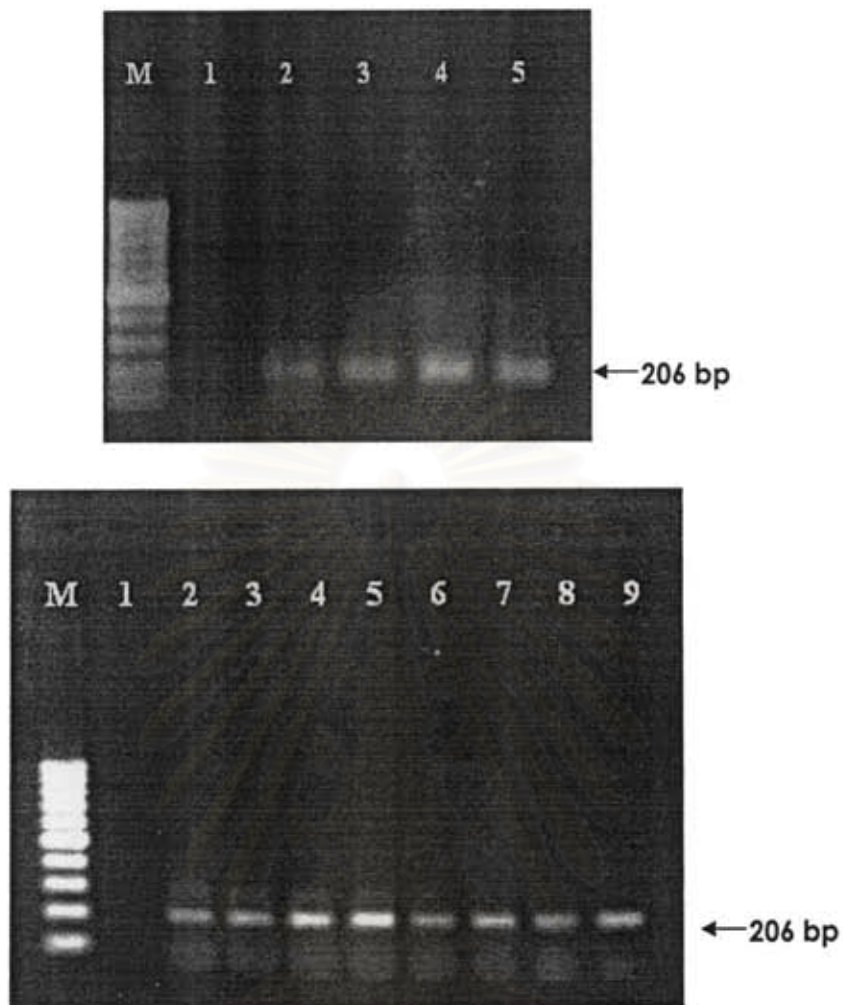


Figure 23. HPRT expression in lungs from hamsters infected with avirulent *Leptospira* at day 3, 7, 14, 21 postinfection. Three hamsters were used for each timepoint. Lane M : marker; Lane 1: negative control. Top figure : Lanes 2,3,4, and 5 were from 3,7,14, and 21 days postinfection, respectively. Bottom figure: Lanes 2, 6 were from 3 days postinfection ; Lanes 3, 7 from 7 days; Lanes 4, 8 from 14 days; Lanes 5, 9 from 21 days postinfection.

จุฬาลงกรณ์มหาวิทยาลัย



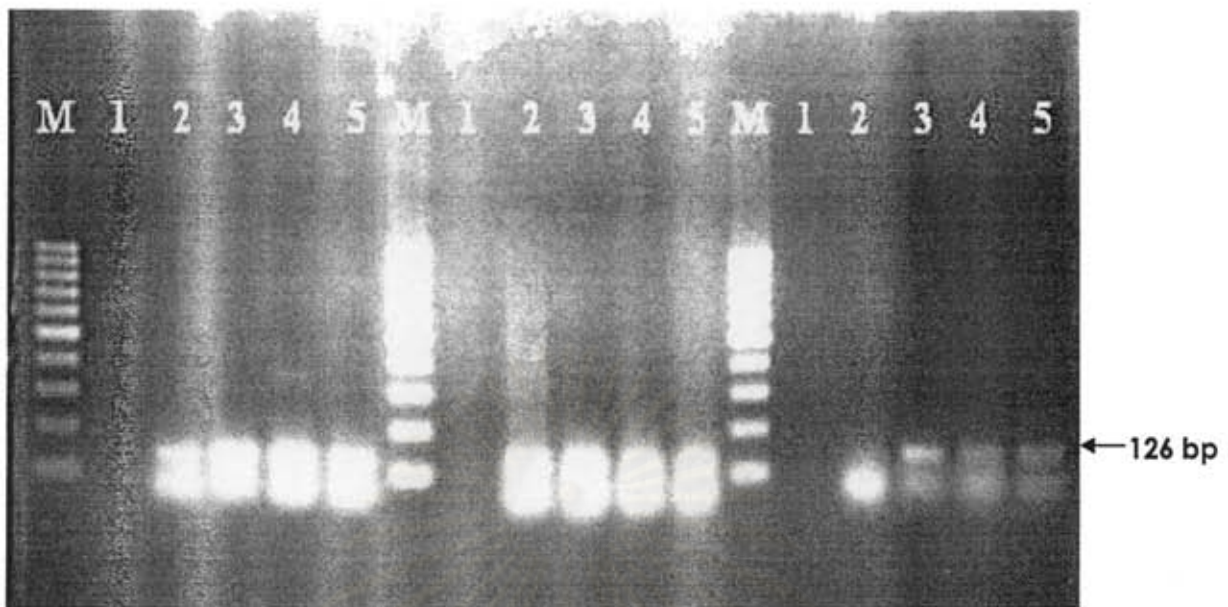

Figure 24. TNF- $\alpha$  expression in kidneys from hamsters infected with avirulent *Leptospira* at 3,7,14, and 21 days post infection. Three hamsters were used for each timepoint. Lane M = 100 bp-marker; Lane 1= negative control; Lanes 2,3,4,5 from 3,7,14,21 days post infection, respectively.

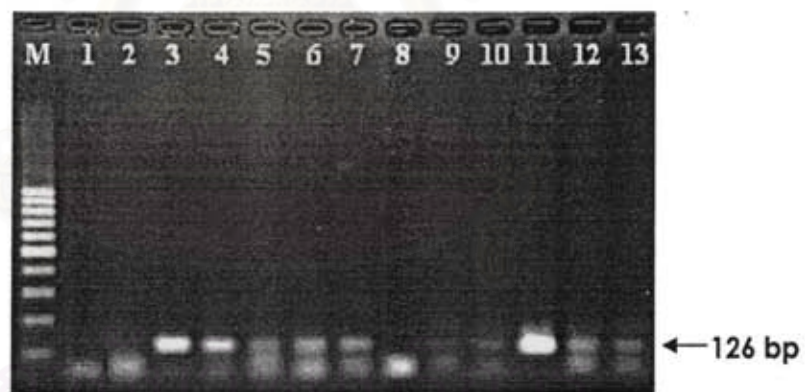

Figure 25. TNF- $\alpha$  expression in livers from hamsters infected with avirulent hamsters. Lane M = 100 bp-marker; Lane 1: negative control; Lane 2, 6,10 were from 3 days postinfection; Lanes 3, 7, 11 from 7 days; Lanes 4, 8, 12 from 14 days; Lanes 5, 9, 13 were from 21 days postinfection.

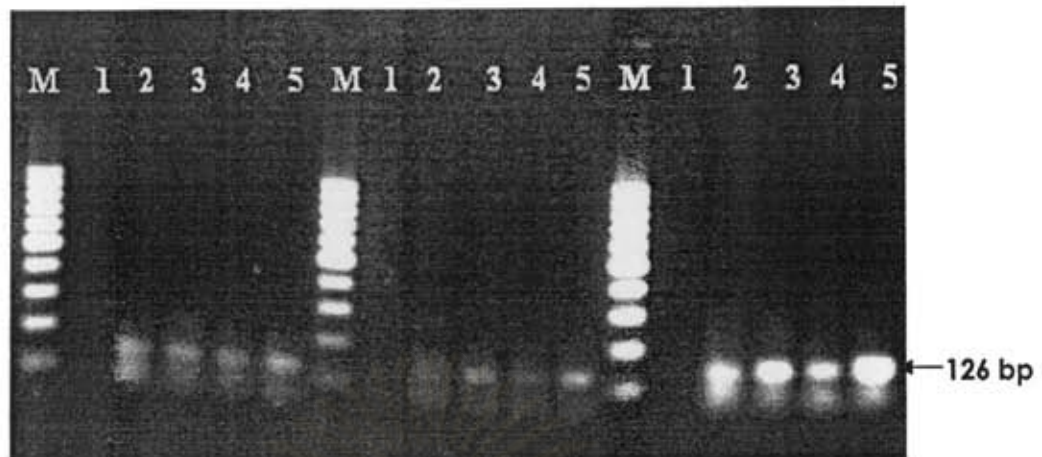


Figure 26. TNF- $\alpha$  expression in lungs from hamsters infected with avirulent *Leptospira* at 3,7,14, and 21 days post infection. Three hamsters were used for each timepoint. Lane M = 100 bp-marker; Lane 1= negative control; Lanes 2,3,4,5 from 3,7,14,21 days post infection, respectively.

สถาบันวิทยบริการ  
จุฬาลงกรณ์มหาวิทยาลัย

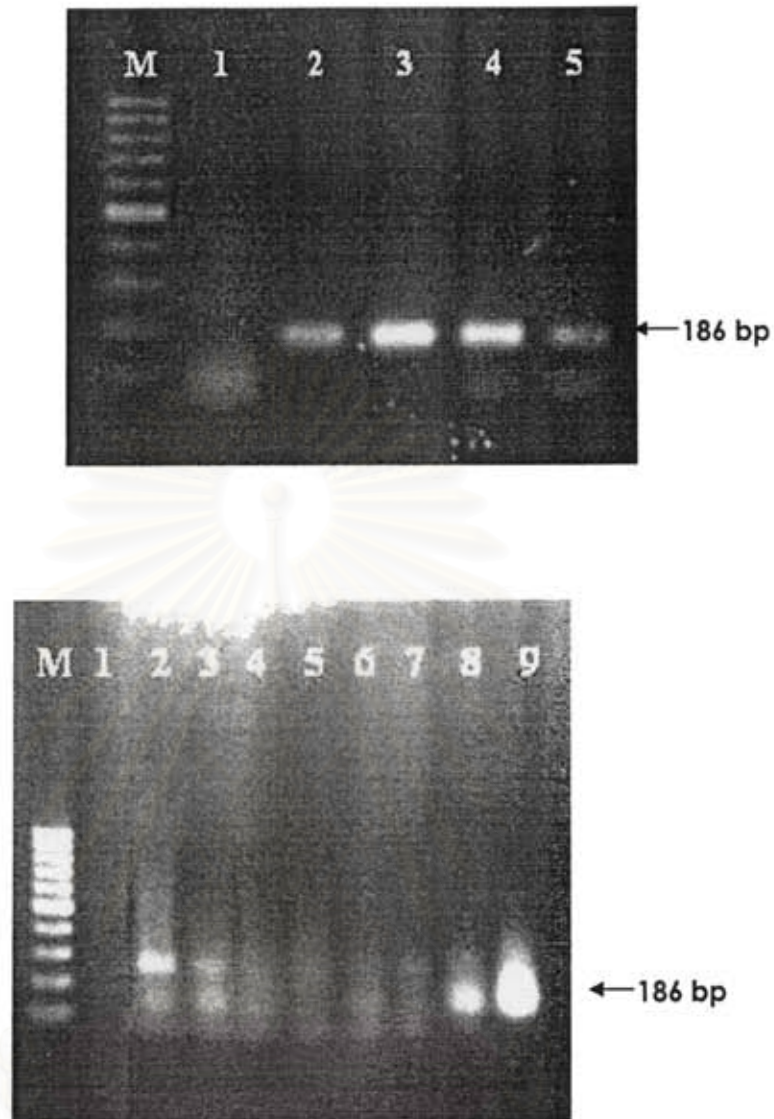


Figure 27. TGF- $\beta$  expression in kidneys from hamsters infected with avirulent *Leptospira* at day 3, 7, 14, 21 postinfection. Three hamsters were used for each timepoint. Lane M : marker; Lane 1: negative control. Top figure : Lanes 2,3,4, and 5 were from 3,7,14, and 21 days postinfection, respectively. Bottom figure: Lanes 2, 6 were from 3 days postinfection ; Lanes 3, 7 from 7 days; Lanes 4, 8 from 14 days; Lanes 5, 9 from 21 days postinfection.

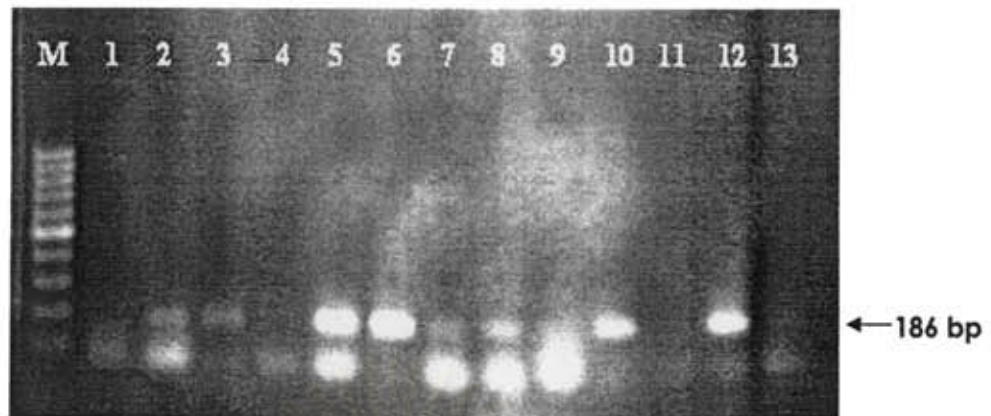


Figure 28. TGF- $\beta$  expression in livers from hamsters infected with avirulent hamsters. Lane M = 100 bp-marker; Lane 1: negative control; Lane 2, 6,10 were from 3 days postinfection; Lanes 3, 7, 11 from 7 days; Lanes 4, 8, 12 from 14 days; Lanes 5, 8, 13 were from 21 days postinfection.

สถาบันวิทยบริการ  
จุฬาลงกรณ์มหาวิทยาลัย

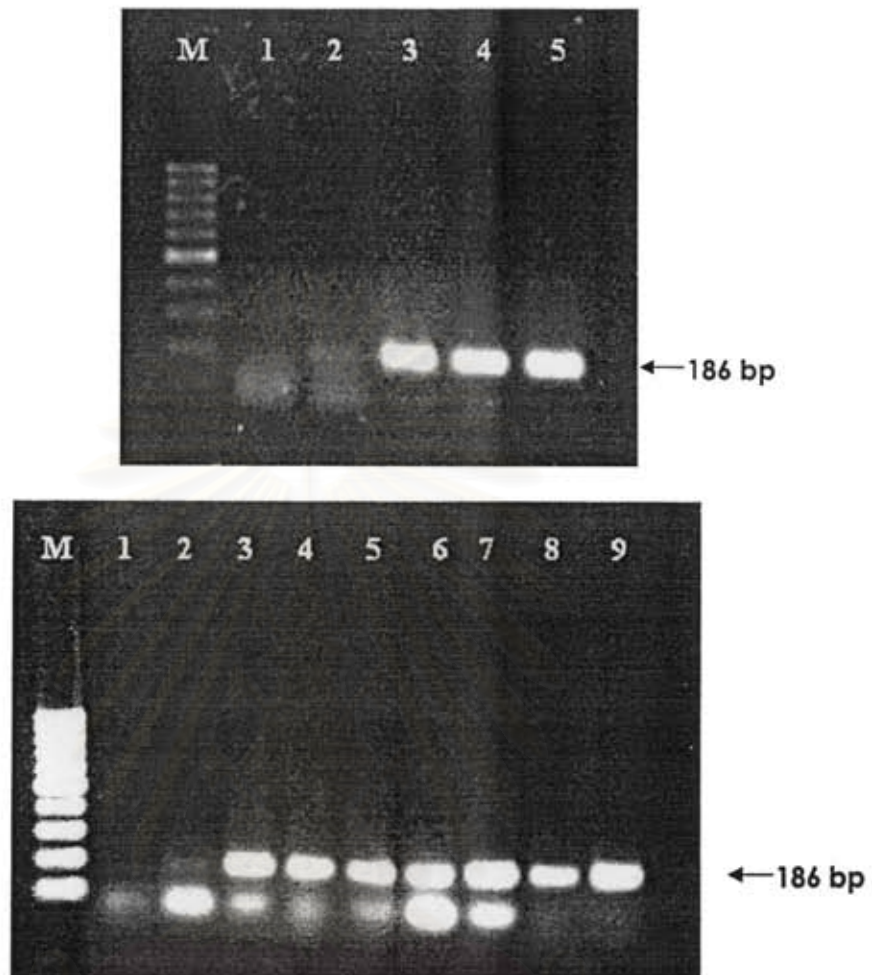


Figure 29. TGF- $\beta$  expression in lungs from hamsters infected with avirulent *Leptospira* at day 3, 7, 14, 21 postinfection. Three hamsters were used for each timepoint. Lane M : marker; Lane 1: negative control. Top figure: Lanes 2,3,4, and 5 were from 3,7,14, and 21 days postinfection, respectively. Bottom figure : Lanes 2, 6 were from 3 days postinfection ; Lanes 3, 7 from 7 days; Lanes 4, 8 from 14 days; Lanes 5, 9 from 21 days postinfection.



Figure 30. IL-10 expression in kidneys from hamsters infected with avirulent hamsters. Lane M = 100 bp-marker; Lane 1: negative control; Lane 2 = positive control; Lane 3, 7, 11 were from 3 days postinfection; Lanes 4, 8, 12 from 7 days; Lanes 5, 9, 13 from 14 days; Lanes 6, 10, 14 were from 21 days postinfection.



Figure 31. IL-10 expression in livers from hamsters infected with avirulent hamsters. Lane M = 100 bp-marker; Lane 1: negative control; Lane 2 = positive control; Lane 3, 7, 11 were from 3 days postinfection; Lanes 4, 8, 12 from 7 days; Lanes 5, 9, 13 from 14 days; Lanes 6, 10, 14 were from 21 days postinfection.



Figure 32. IL-10 expression in lungs from hamsters infected with avirulent hamsters. Lane M = 100 bp-marker; Lane 1: negative control; Lane 2 = positive control; Lane 3, 7,11 were from 3 days postinfection; Lanes 4, 8, 12 from 7 days; Lanes 5, 9, 13 from 14 days; Lanes 6, 10, 14 were from 21 days postinfection.

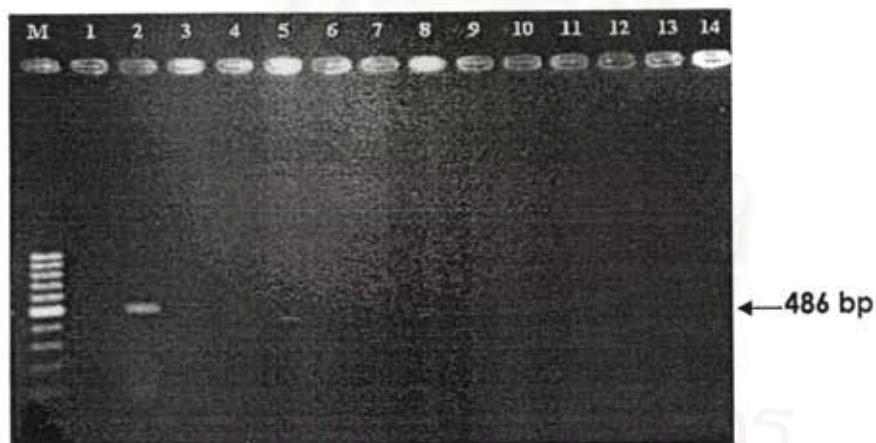


Figure 33. IP-10 expression in kidneys from hamsters infected with avirulent hamsters. Lane M = 100 bp-marker; Lane 1: negative control; Lane 2 = positive control; Lane 3, 7,11 were from 3 days postinfection; Lanes 4, 8, 12 from 7 days; Lanes 5, 9, 13 from 14 days; Lanes 6, 10, 14 were from 21 days postinfection.

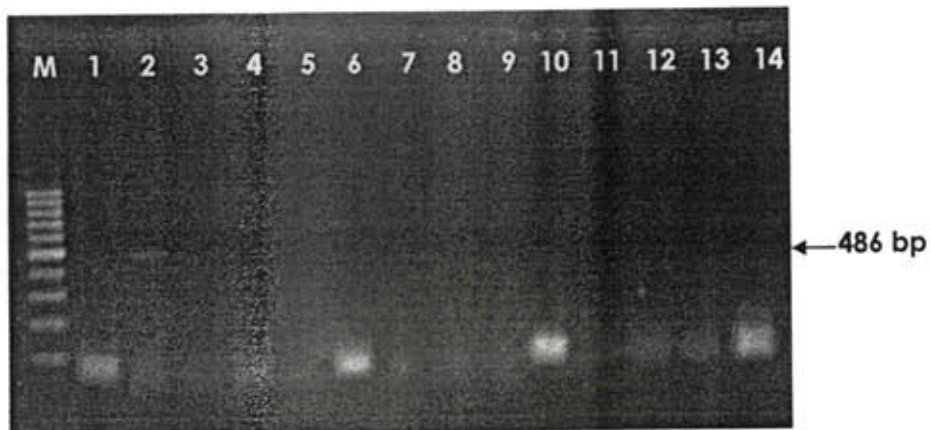

Figure 34. IP-10 expression livers from hamsters infected with avirulent hamsters. Lane M = 100 bp-marker; Lane 1: negative control; Lane 2 = positive control; Lane 3, 7,11 were from 3 days postinfection; Lanes 4, 8, 12 from 7 days; Lanes 5, 9, 13 from 14 days; Lanes 6, 10, 14 were from 21 days postinfection

สถาบันวิทยบริการ  
จุฬาลงกรณ์มหาวิทยาลัย



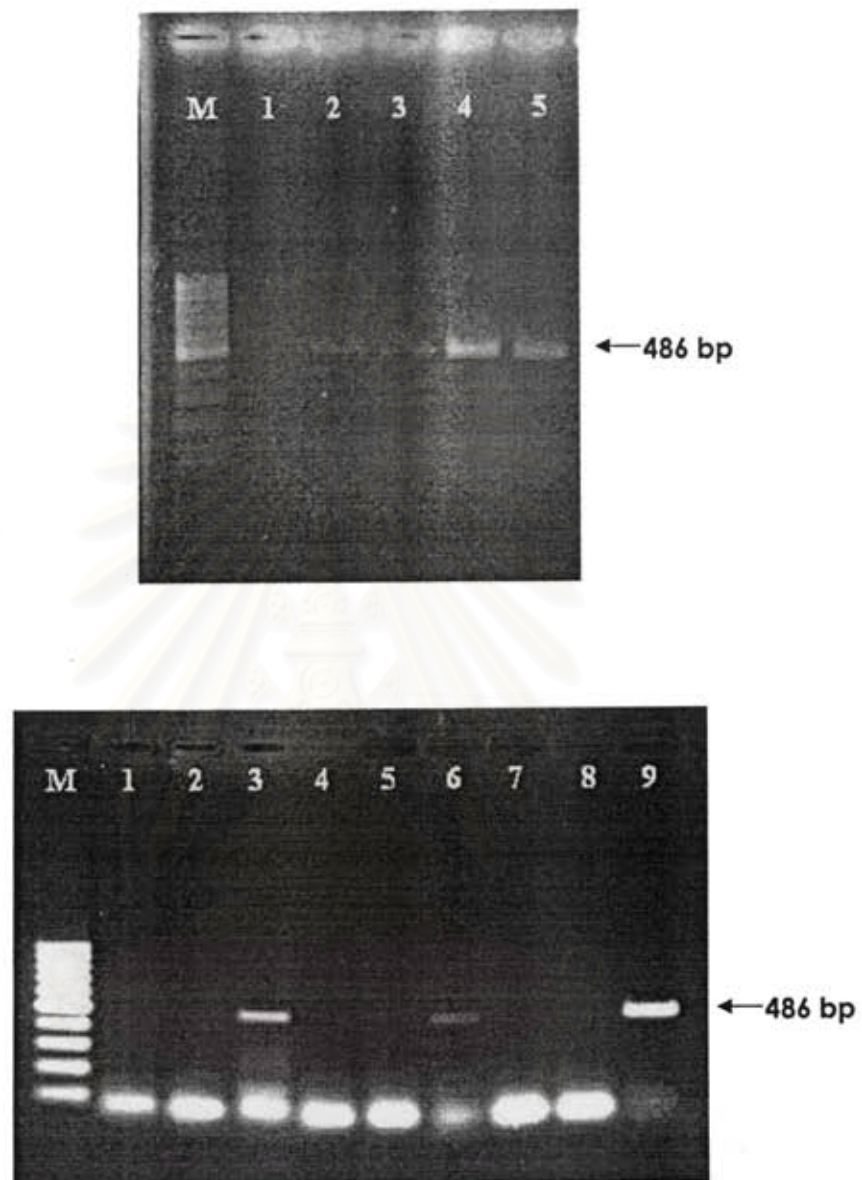


Figure 35. IP-10 expression in lungs from hamsters infected with avirulent *Leptospira* at day 3, 7, 14, 21 postinfection. Three hamsters were used for each timepoint. Lane M : marker; Lane 1: negative control. Top figure: Lanes 2,3,4, and 5 were from 3,7,14, and 21 days postinfection, respectively. Bottom figure: Lanes 2, 6 were from 3 days postinfection ; Lanes 3, 7 from 7 days; Lanes 4, 8 from 14 days; Lanes 5, 9 from 21 days postinfection.

### *Leptospira* 16S rRNA mRNA expression in kidneys, livers and lungs

16S rRNA expression was detected in all kidney, liver and lung tissues of virulent group (Figures 37-39). The presence of 16S rRNA suggested that there were organisms in these organs. *Leptospira* 16S rRNA was detected since day 3 postinfection. However, 16S rRNA was not observed in tissues from avirulent group even in day 3 samples (Figures 40-42). The organisms might be cleared from animals by the time specimens were collected from this group. No *Leptospira* 16S rRNA was detected in tissues from non-infected hamsters (Figure 36).

### *LipL21, LipL32 and collagenase mRNA expression in kidneys, livers and lungs*

LipL21, LipL32 and collagenase gene expression was investigated to demonstrate whether these genes were expression *in vivo*. Nested PCR was conducted for LipL21 and LipL32 since their expression could not be detected from the first round PCR. Since 16S rRNA was not detectable in tissues from avirulent group, the expression of other leptospiral genes was investigated only in tissues from virulent group.

Expression of LipL21 (Figures 44, 45 and 46), LipL32 (Figures 48, 49, and 50) and collagenase (Figures 52, 53 and 54) in kidney, liver and lung tissues were demonstrated. There was no PCR products of LipL21, LipL32 and collagenase detected in tissues from non-infected hamsters (Figures 43, 47 and 51).

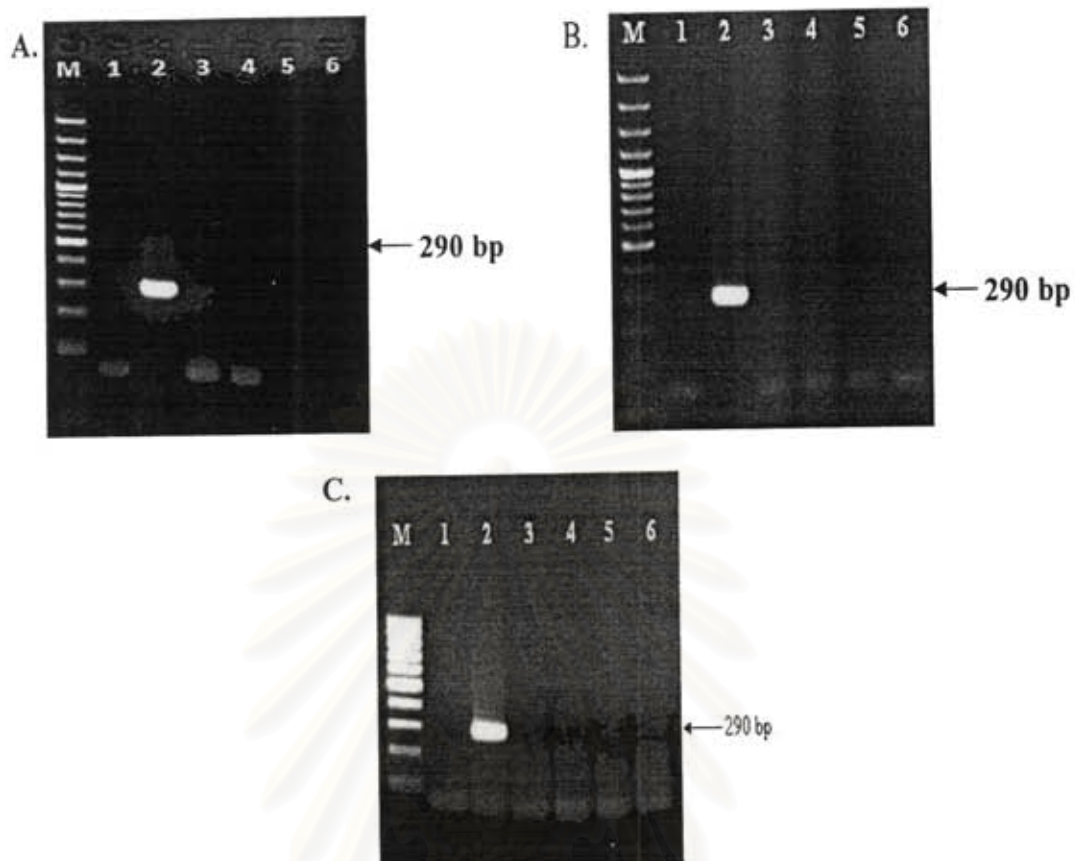


Figure 36. 16S rRNA expression in kidneys, livers and lungs (A, B and C, respectively) from non-infected hamsters. Four hamsters were used (Lanes 3-6). M = 100-bp marker, Lane 1 = negative control; Lane 2 : positive control.

สถาบันวิทยบริการ  
จุฬาลงกรณ์มหาวิทยาลัย

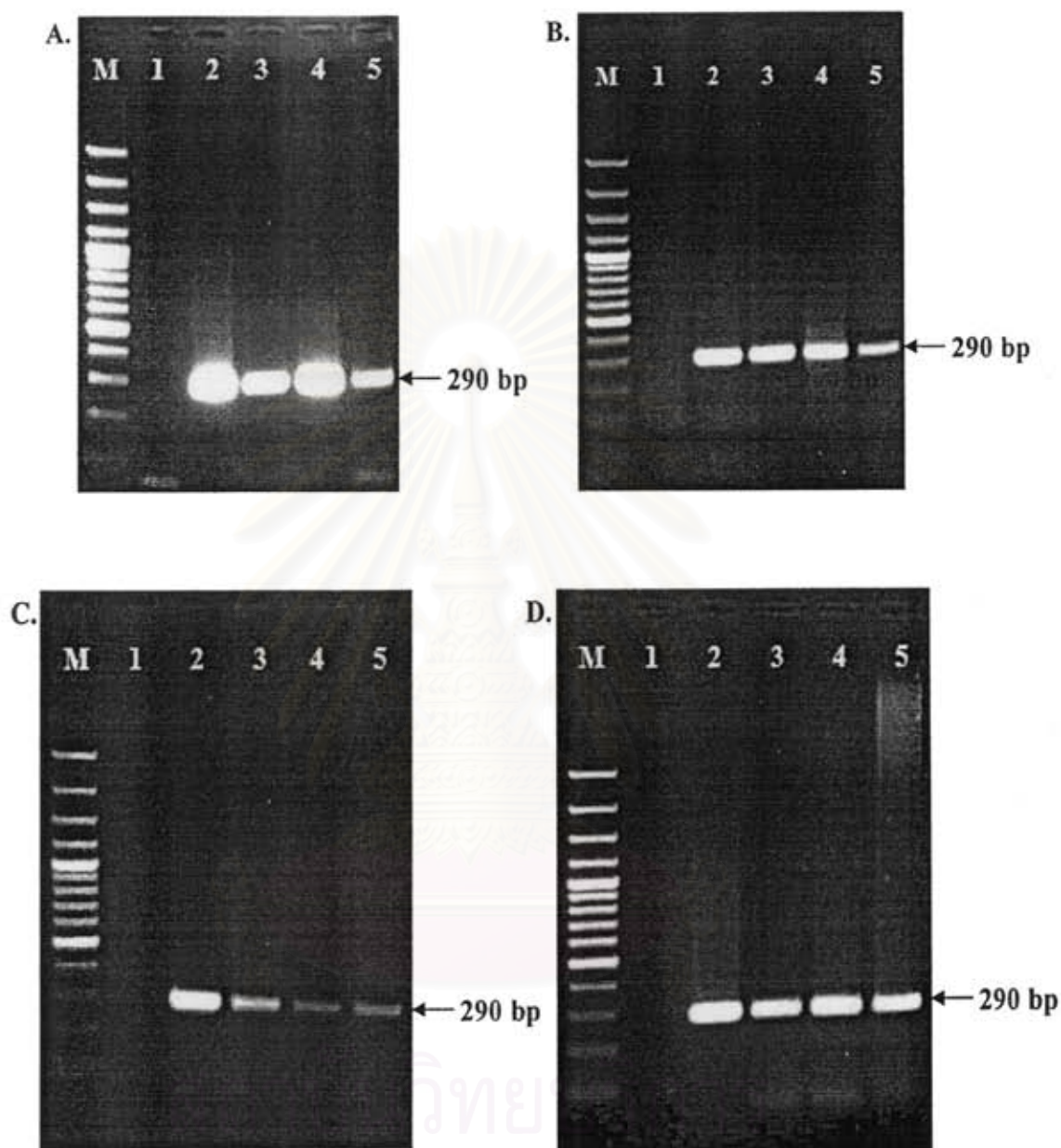


Figure 37. 16S rRNA expression of kidneys from hamsters infected with virulent *Leptospira* at 3, 5, 7 days post infection (Laned 3, 4 and 5, respectively). Four hamsters were used for each timepoint (A-D). M = 100-bp marker; Lane 1 = negative control, Lane 2 = positive control.

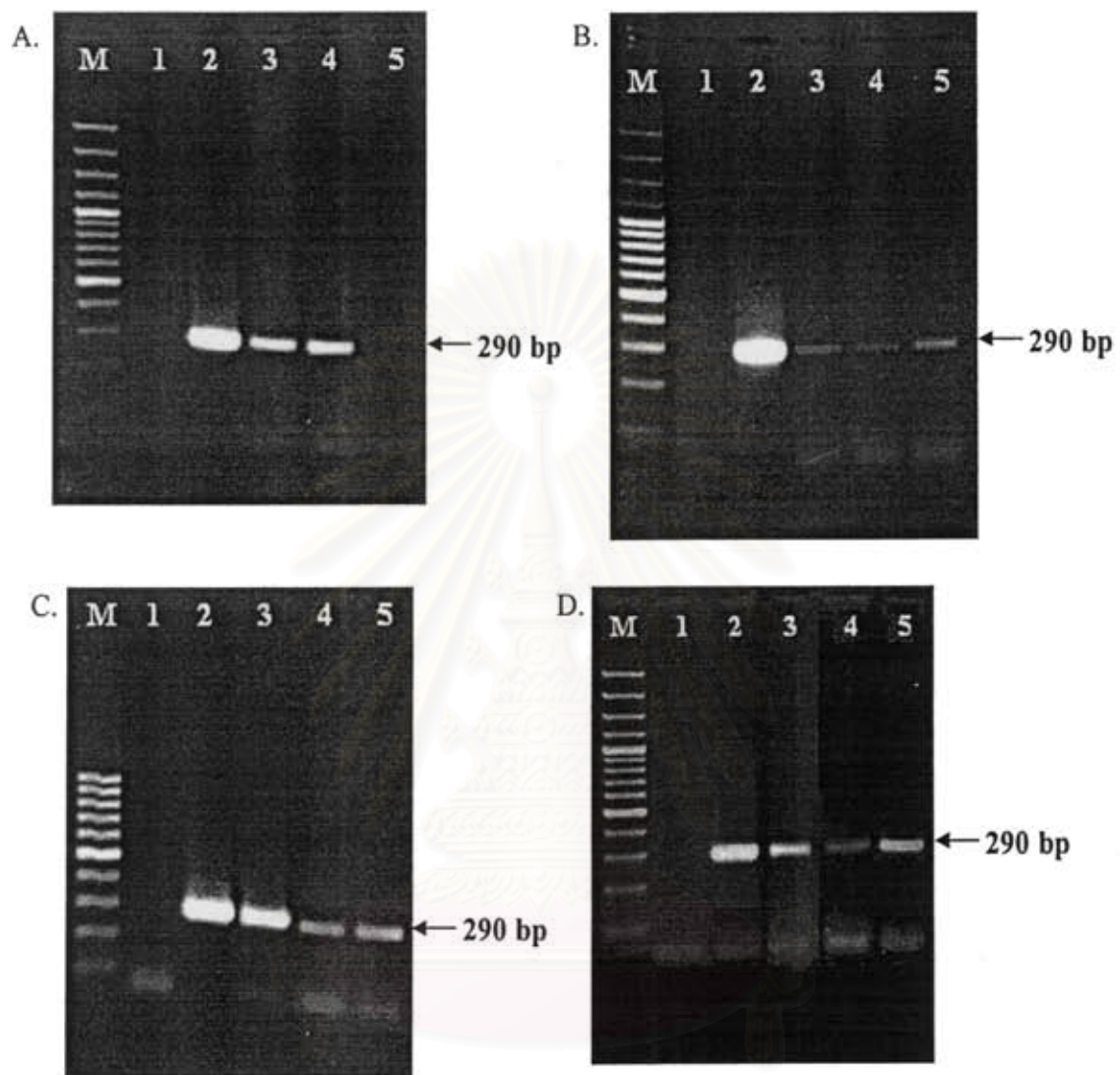


Figure 38. 16S rRNA expression in livers from hamsters infected with virulent *Leptospira* at 3, 5, 7 days post infection (Laned 3, 4 and 5, respectively). Four hamsters were used for each timepoint (A-D). M = 100-bp marker; Lane 1 = negative control, Lane 2 = positive control.

จุฬาลงกรณ์มหาวิทยาลัย

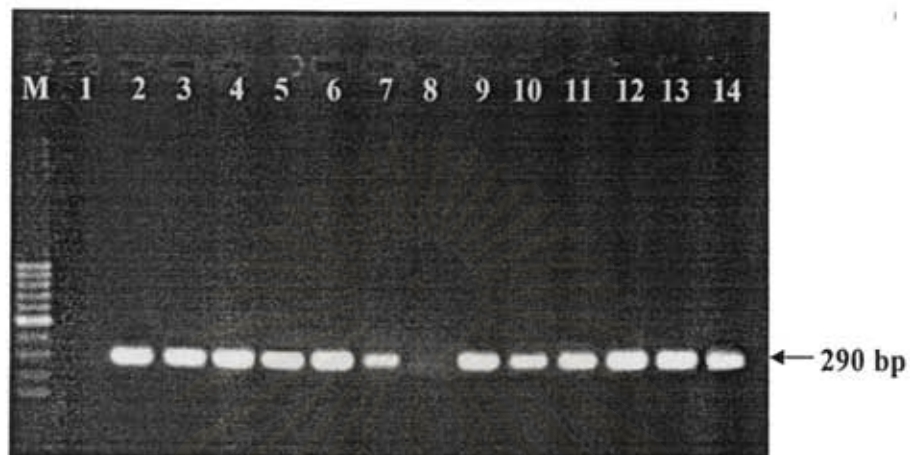


Figure 39. 16S rRNA expression in lungs of hamsters infected with virulent *Leptospira* at 3, 5, 7 days postinfection. Four hamsters were used for each timepoint. M = 100-bp marker; Lane 1 : negative control; Lane 2 = positive control; Lanes 3, 6, 9,12 = 3 days postinfection; Lanes 4, 7, 10, 13 = 5 days postinfection; Lanes 5, 8,11, 14 = 7 days postinfection

สถาบันวิทยบริการ  
จุฬาลงกรณ์มหาวิทยาลัย

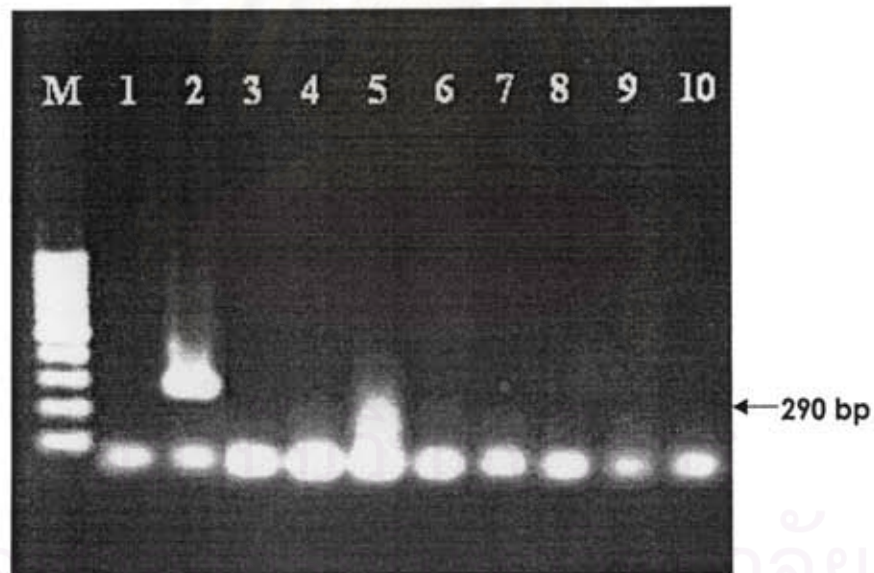
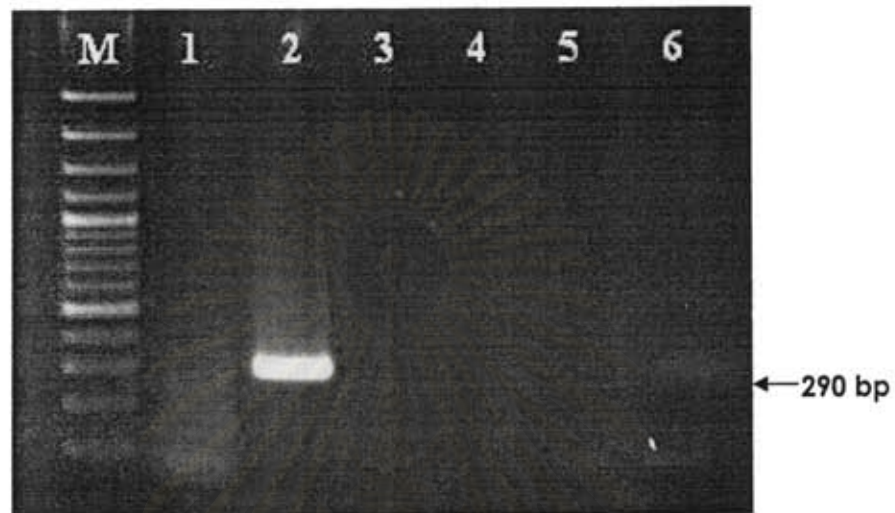


Figure 40. 16 S rRNA expression in kidneys of hamsters infected with avirulent *Leptospira*. Lane M : marker; Lane 1: negative control; Lane 2: positive control. Fig. 40 (top) : Lanes 3,4,5,6 were from 3,7,14,21 days post infection. Fig. 40 (bottom) : Lanes 3, 7 were from 3 days postinfection; Lanes 4, 8 from 7 days; Lanes 5, 9 from 14 days; Lanes 6, 10 from 21 days postinfection.

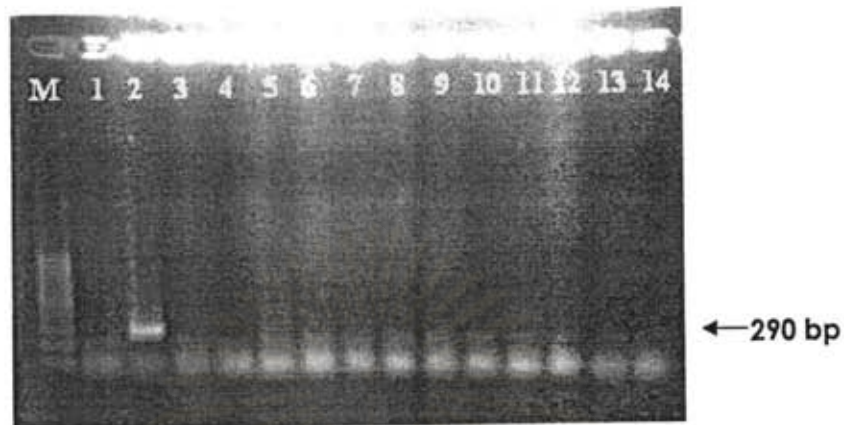


Figure 41. 16 S rRNA expression in livers from hamsters infected with avirulent *Leptospira*. Lane M : marker; Lane 1: negative control; Lane 2: positive control; Lane 3, 7,11 were from 3 days postinfection; Lanes 4, 8, 12 from 7 days; Lanes 5, 9, 13 from 14 days; Lanes 6, 10, 14 were from 21 days postinfection

สถาบันวิทยบริการ  
จุฬาลงกรณ์มหาวิทยาลัย



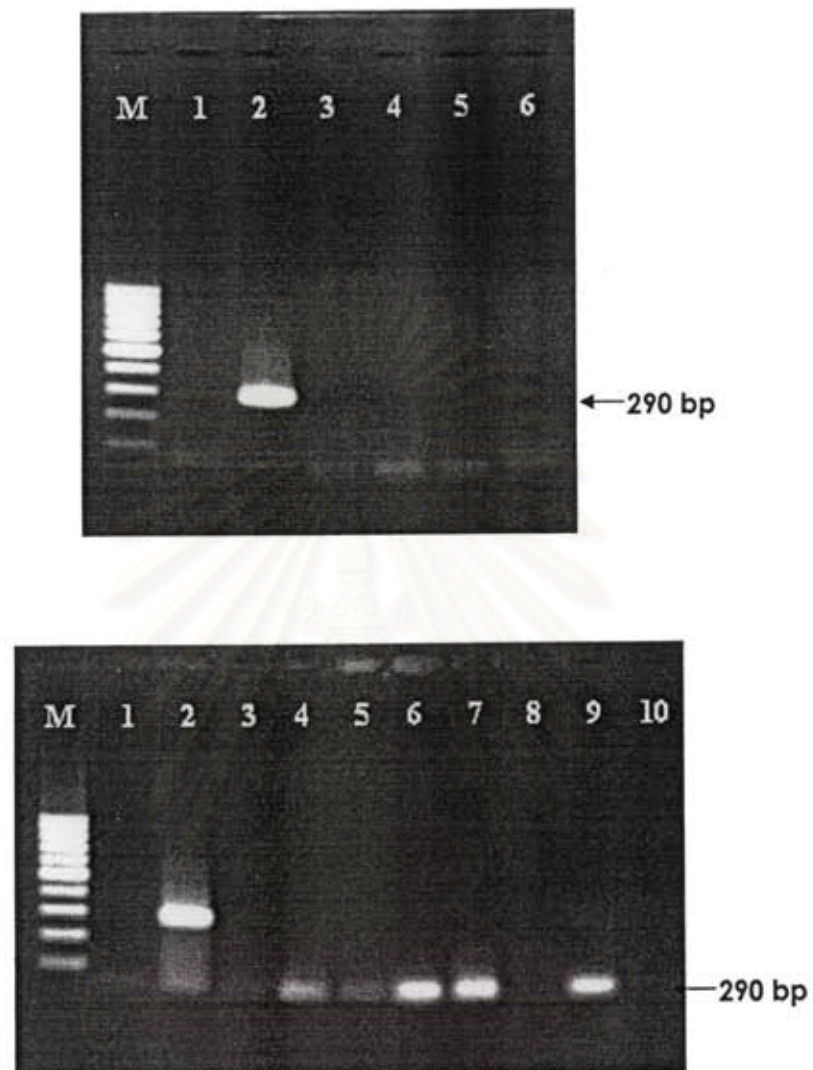


Figure 42. 16 S rRNA expression in lungs of hamsters infected with avirulent *Leptospira*. Lane M : marker; Lane 1: negative control; Lane 2: positive control. Fig. 42 (top) : Lanes 3,4,5,6 were from 3,7,14,21 days post infection. Fig. 42 (bottom) : Lanes 3, 7 were from 3 days postinfection; Lanes 4, 8 from 7 days; Lanes 5, 9 from 14 days; Lanes 6, 10 from 21 days postinfection.

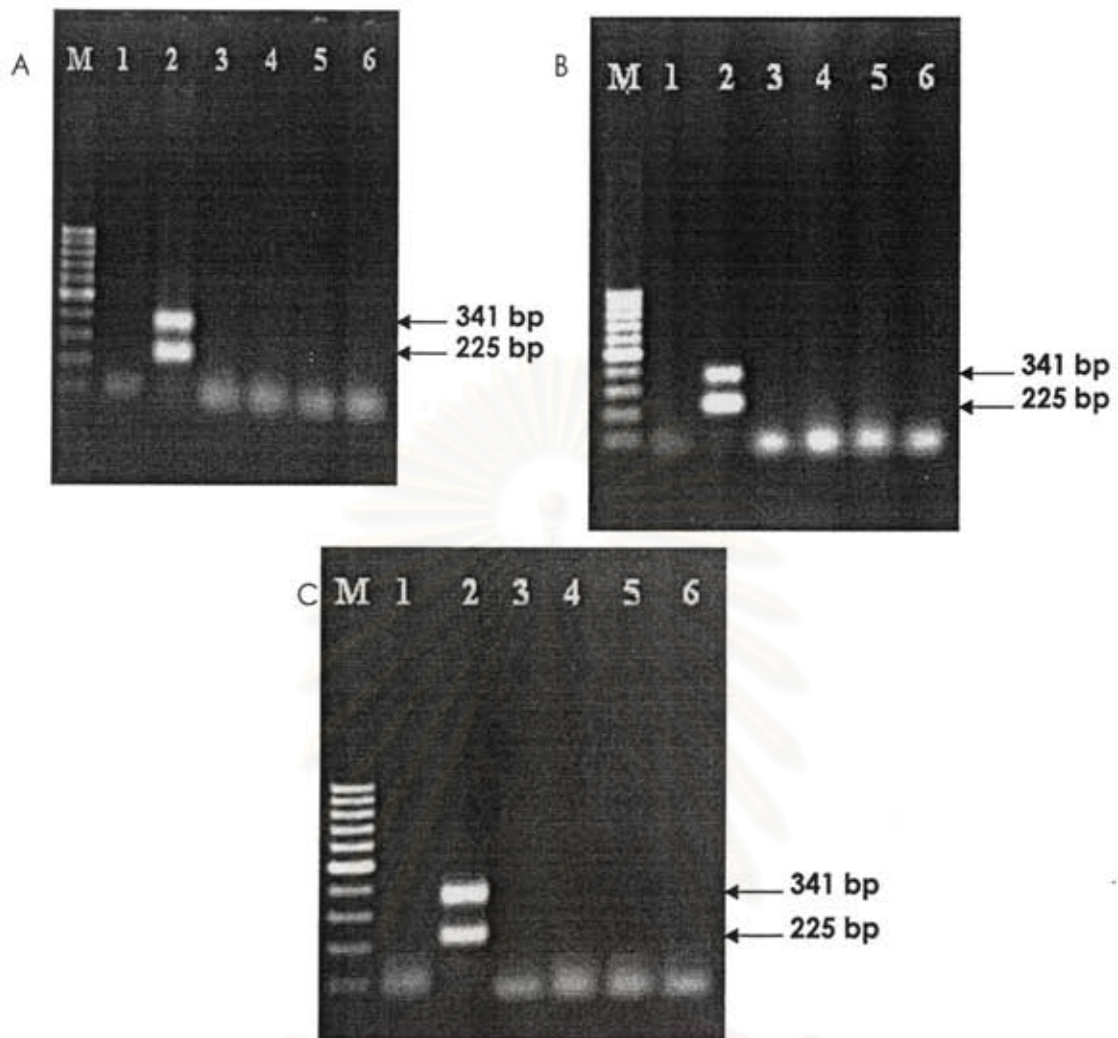


Figure 43. LipL21 expression in kidneys (A), livers (B) and lungs (C) from non-infected hamsters. Four hamsters were used (Lanes 3-6). M:= 100-bp marker; Lane1:= negative control; Lane 2 = positive control.

สถาบันวิทยบริการ  
จุฬาลงกรณ์มหาวิทยาลัย

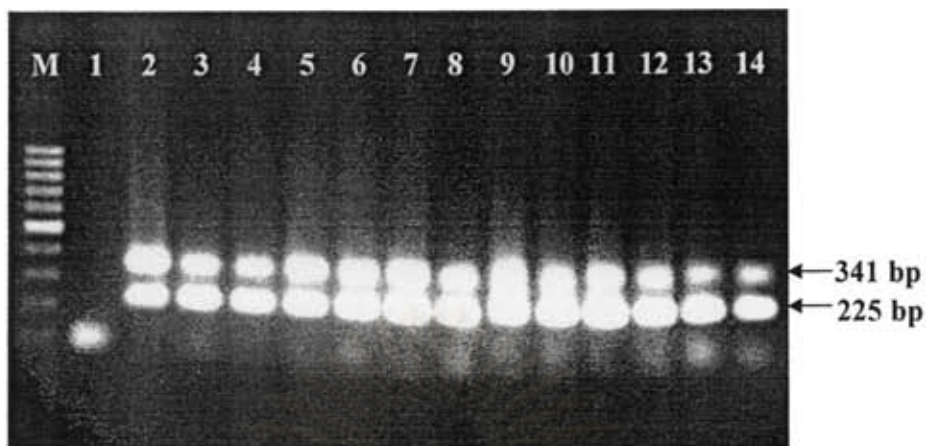


Figure 44. LipL21 expression in kidneys from hamsters infected with virulent *Leptospira* at 3, 5, 7 days post infection. Four hamsters were used for each timepoint. M = 100 bp- marker; Lane 1 : negative control; Lane 2 = positive control; Lanes 3, 6, 9,12 = 3 days postinfection; Lanes 4, 7, 10, 13 = 5 days postinfection; Lanes 5, 8,11, 14 = 7 days postinfection.



Figure 45 LipL21 expression in livers from hamsters infected with virulent *Leptospira* at 3, 5, 7 days post infection. Four hamsters were used for each timepoint. M = 100 bp- marker; Lane 1 : negative control; Lane 2 = positive control; Lanes 3, 6, 9,12 = 3 days postinfection; Lanes 4, 7, 10, 13 = 5 days postinfection; Lanes 5, 8,11, 14 = 7 days postinfection.

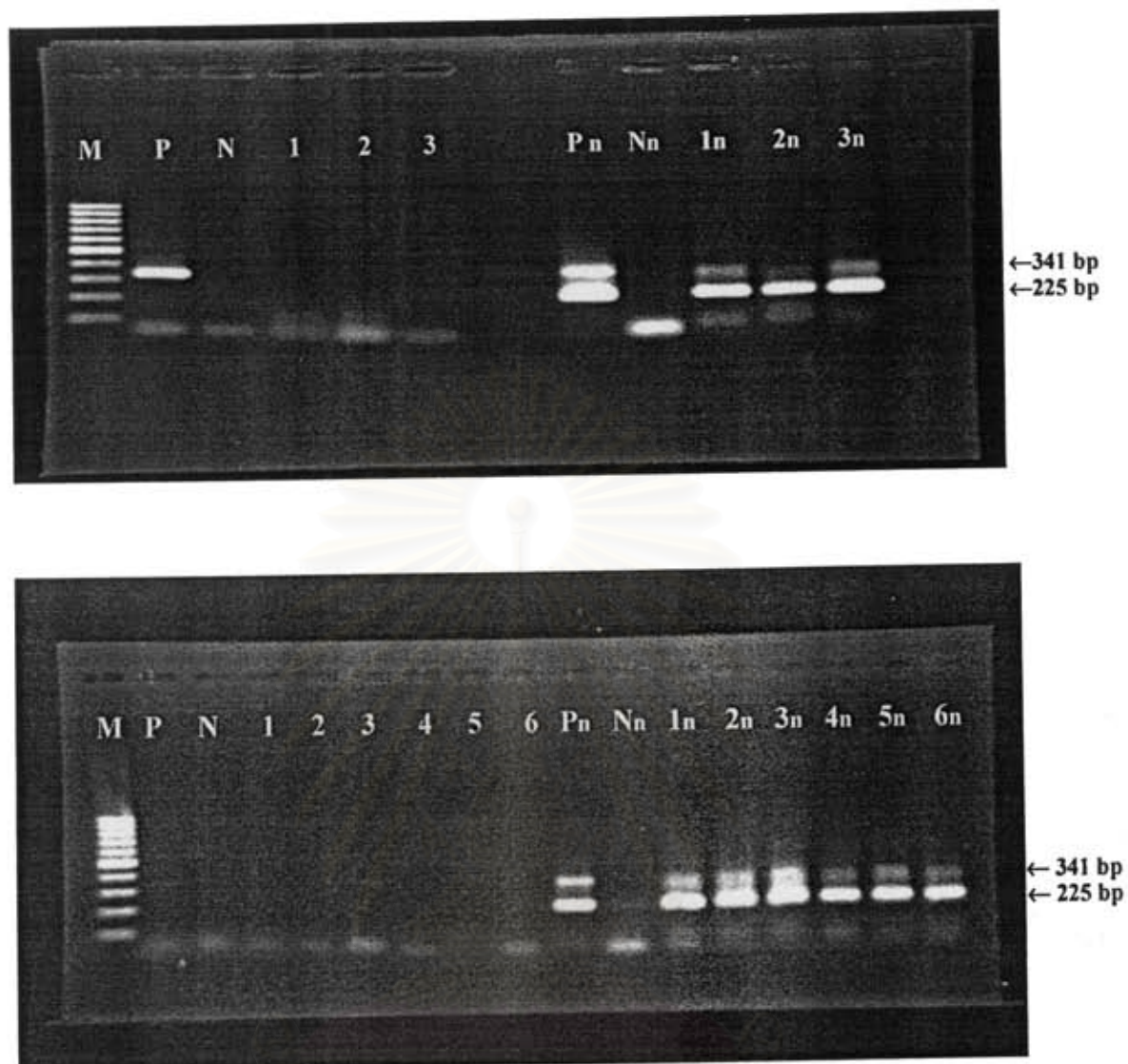


Figure 46. LipL21 expression in lungs from hamsters infected with virulent *Leptospira*. at days 3,5,7 postinfection. Nested RT-PCR was performed and products from both rounds were shown. M = 100-bp marker; P = Positive control; , N = Negative control; Pn = positive control from second round; Nn = negative control from second round; n represents second round product Fig. 46 (top) : Lanes 1, 2, and 3 were from 3, 5 and 7 days postinfection. Fig. 46 (bottom) : Lanes 1, 4 were from 3 days postinfection; Lanes 2, 5 from 5 days; Lanes 3, 6 were from 7 days postinfection.

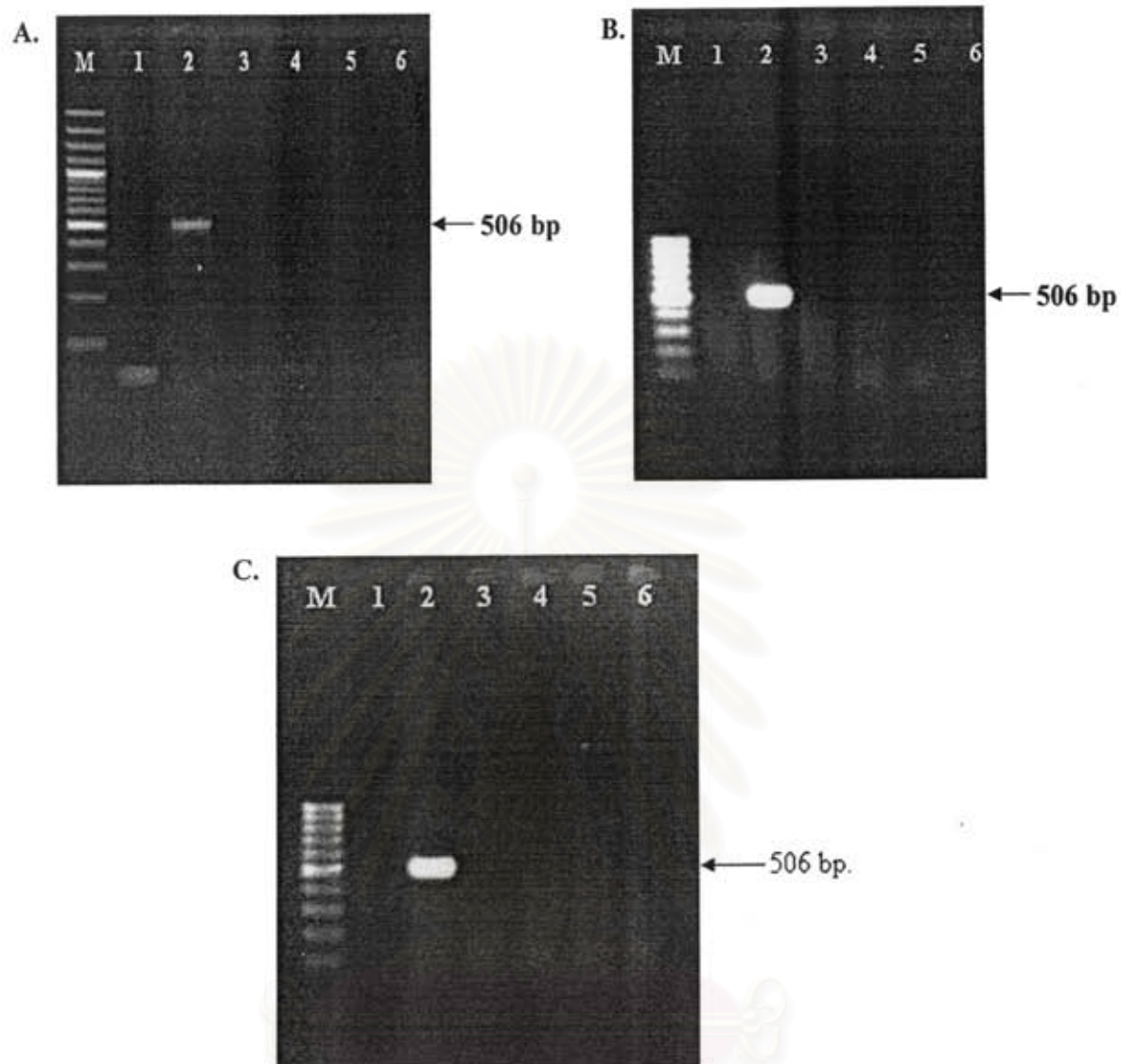


Figure 47. LipL32 expression in kidneys (A), liver (B) and lungs (C) from non-infected hamsters. M = 100-bp marker; Lane 1 = negative control, Lane 2 = positive control. Four hamsters were used (Lanes 3-6).

สถาบันวิทยบริการ  
จุฬาลงกรณ์มหาวิทยาลัย

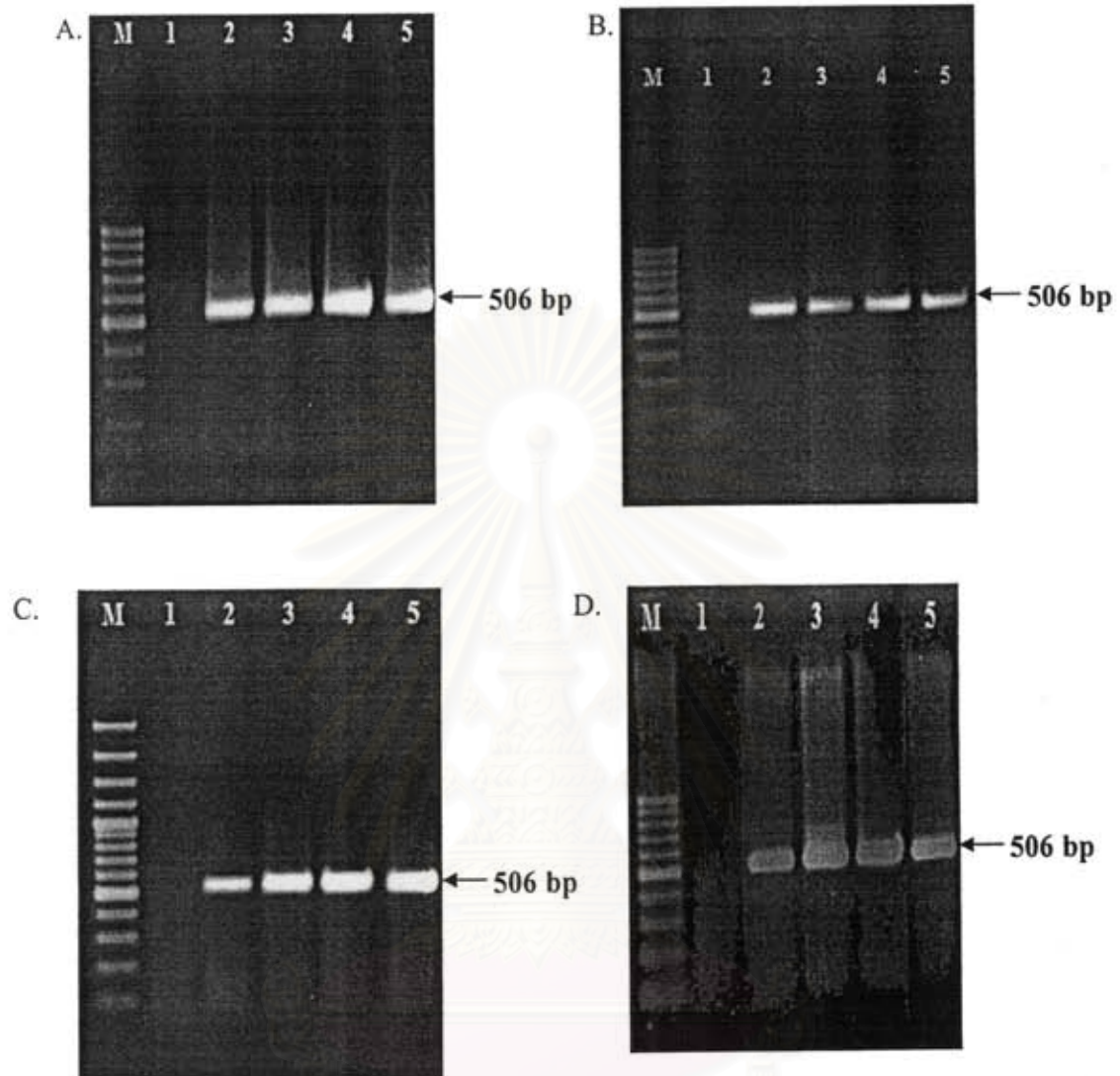


Figure 48. LipL32 expression in kidneys from hamsters infected with virulent *Leptospira* at days 3, 5 and 7 postinfection (Lanes 3, 4, 5 and 6, respectively). Four hamsters were used for each timepoint (A-D). M = 100-bp marker, Lane 1 = negative control Lane 2 = positive control.

จุฬาลงกรณ์มหาวิทยาลัย

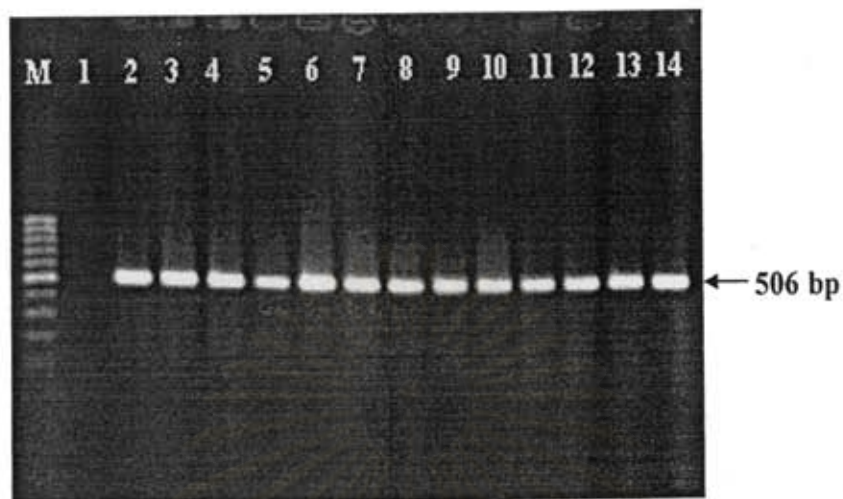


Figure 49. LipL32 expression in livers from hamsters infected with virulent *Leptospira* at 3, 5, 7 days post infection. Four hamsters were used for each timepoint. M = 100 bp- marker; Lane 1 : negative control; Lane 2 = positive control; Lanes 3, 6, 9,12 = 3 days postinfection; Lanes 4, 7, 10, 13 = 5 days postinfection; Lanes 5, 8,11, 14 = 7 days postinfection.

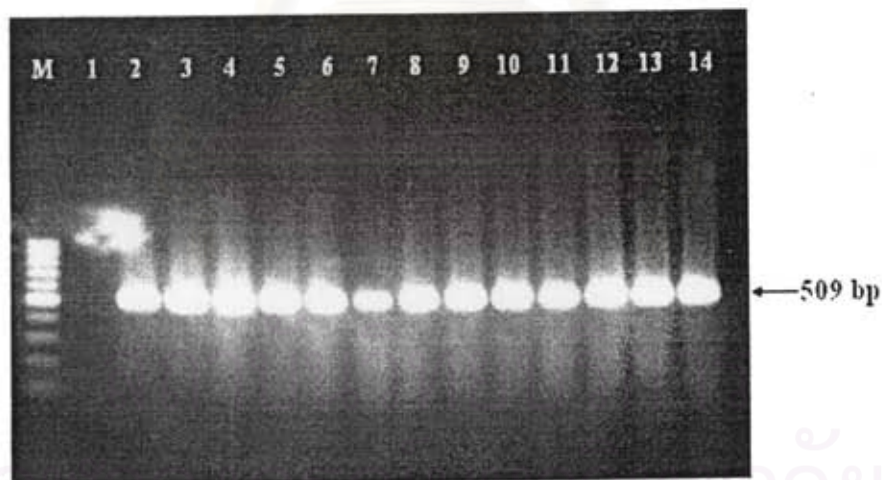


Figure 50. LipL32 expression in lungs from hamsters infected with virulent *Leptospira* at 3, 5, 7 days post infection. Four hamsters were used for each timepoint. M = 100 bp- marker; Lane 1 : negative control; Lane 2 = positive control; Lanes 3, 6, 9,12 = 3 days postinfection; Lanes 4, 7, 10, 13 = 5 days postinfection; Lanes 5, 8,11, 14 = 7 days postinfection.

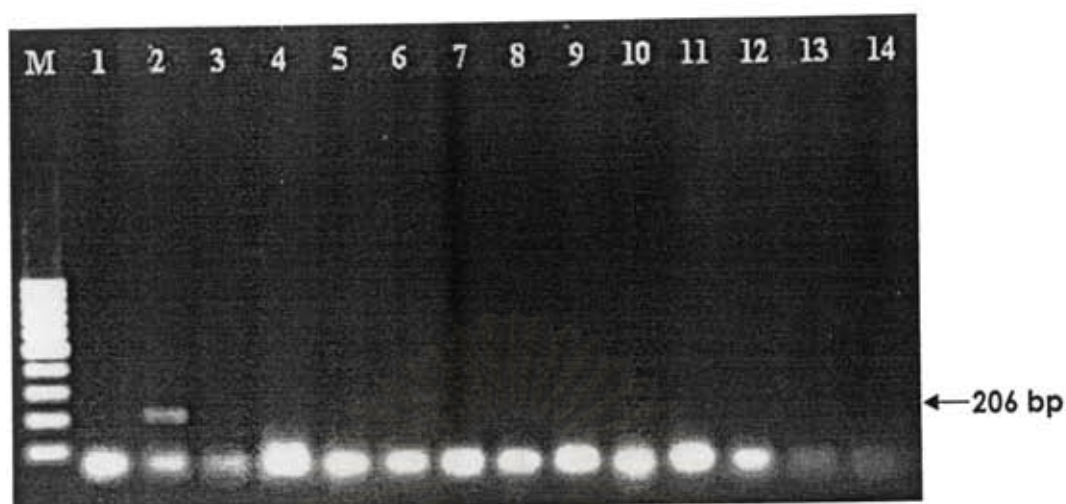


Figure 51. Collagenase expression in kidneys (Lanes 3-6), livers (Lanes 7-10), and lungs (Lanes 11-14) from non-infected hamsters. M = 100-bp marker; Lane 1 = negative control; Lane 2 = positive control.

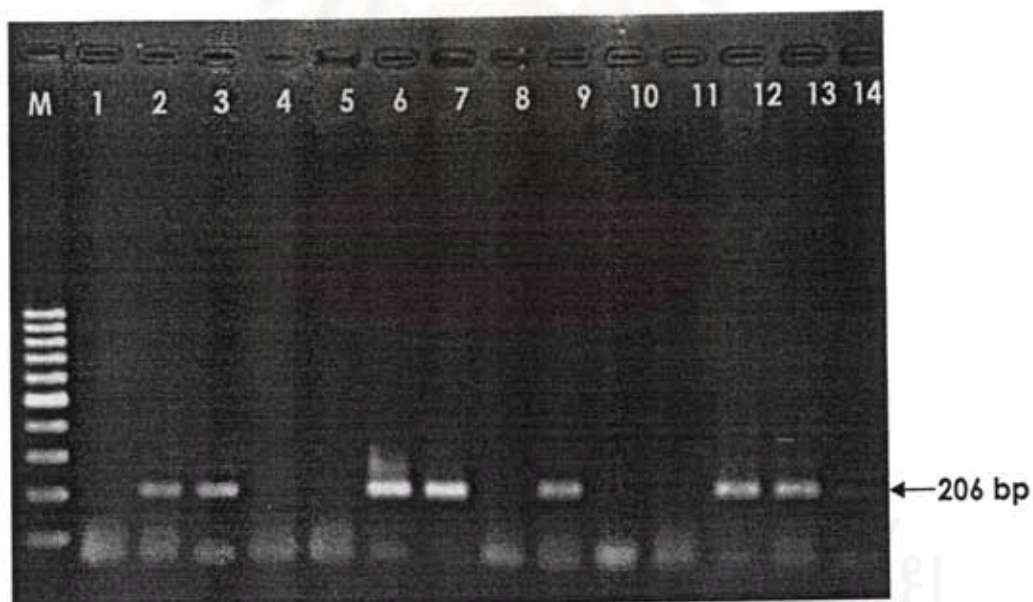

Figure 52. Collagenase expression in kidneys from hamsters infected with virulent *Leptospira* at 3, 5, 7 days post infection. Four hamsters were used for each timepoint. M = 100-bp marker; Lane 1 : negative control; Lane 2 = positive control; Lanes 3, 6, 9, 12 = 3 days postinfection; Lanes 4, 7, 10, 13 = 5 days postinfection; Lanes 5, 8, 11, 14 = 7 days postinfection.





Figure 53. Collagenase expression in livers from hamsters infected with virulent *Leptospira* at 3, 5, 7 days post infection. Four hamsters were used for each timepoint. M = 100 bp- marker; Lane 1 : negative control; Lane 2 = positive control; Lanes 3, 6, 9,12 = 3 days postinfection; Lanes 4, 7, 10, 13 = 5 days postinfection; Lanes 5, 8,11, 14 = 7 days postinfection.

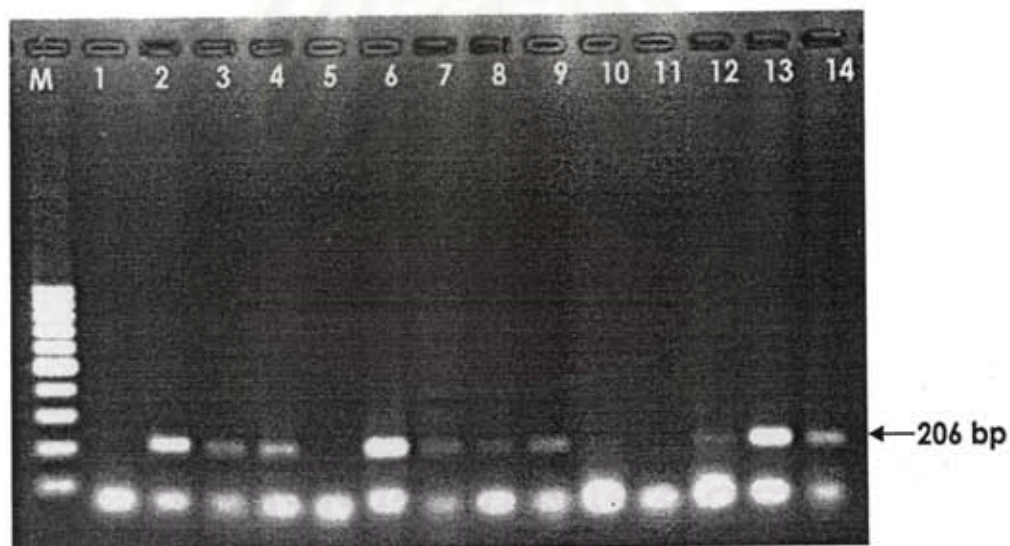


Figure 54. Collagenase expression in lungs from hamsters infected with virulent *Leptospira* at 3, 5, 7 days post infection. Four hamsters were used for each timepoint. M = 100 bp- marker; Lane 1 : negative control; Lane 2 = positive control; Lanes 3, 6, 9,12 = 3 days postinfection; Lanes 4, 7, 10, 13 = 5 days postinfection; Lanes 5, 8,11, 14 = 7 days postinfection.

*Comparison of LipL21, Lip32 and collagenase expression in avirulent and virulent Leptospira.*

RNA was extracted from avirulent or virulent *Leptospira* and RT-PCR was performed using the same method as RT-PCR from tissue samples. Figures 55 demonstrated expression of LipL21, LipL32 and collagenase. Ratio between density of each gene product and 16S rRNA suggested that expression of LipL21m LipL32 and collagenase in virulent *Leptospira* was relatively higher than in avirulent isolate. However, further experiment such as real-time PCR should be done in order to quantitate amount of expression.

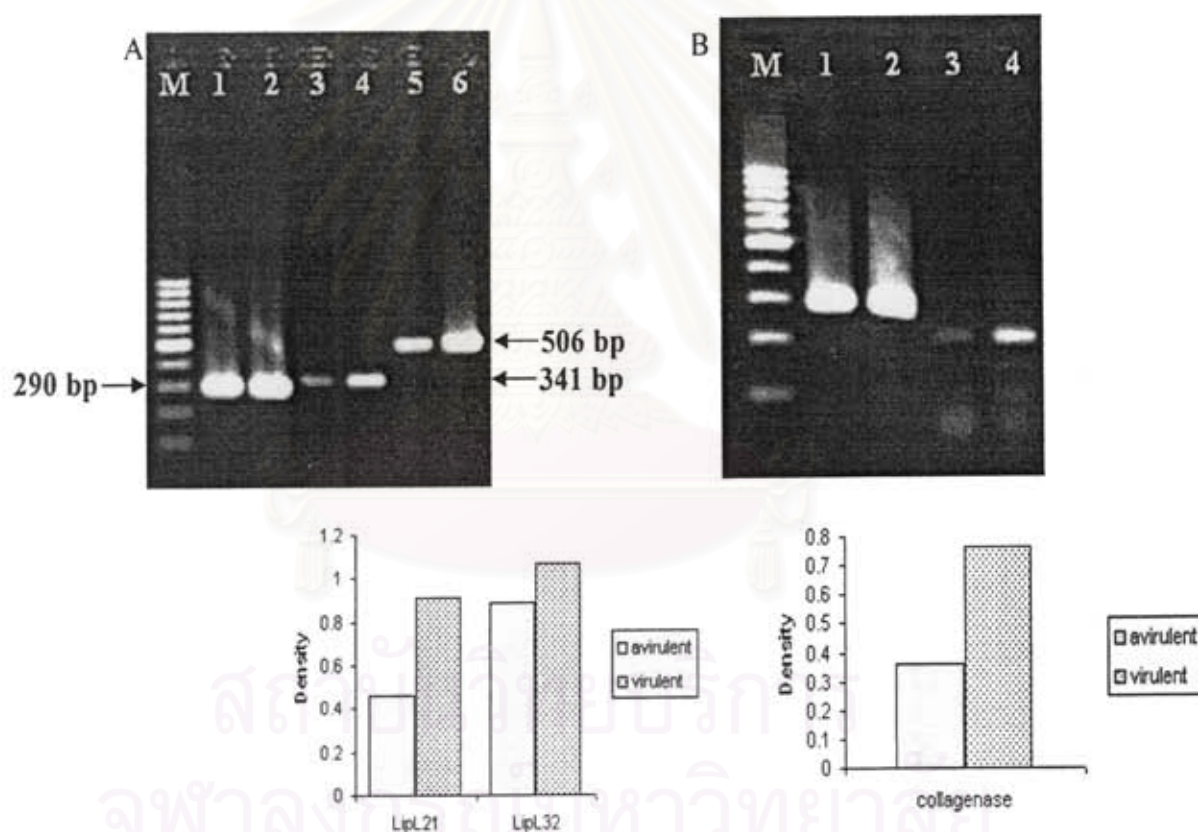


Figure 55. LipL21, LipL32 and collagenase gene expression in avirulent and virulent *Leptospira*. RNA was extracted from avirulent (Lanes 1, 3 and 5) and virulent (Lanes 2, 4, 6) *Leptospira interrogans* serovar Pyrogenase, the isolate used in this study. RT-PCR was performed for the detection of 16S rRNA (Lanes 1 and 2 in both Fig. A and B), LipL21 (Fig. A Lanes 3 and 4), LipL32 (Fig. A, Lanes 5, and 6) and collagenase (Fig. B, Lanes 3 and 4) mRNA expression. Ratio between density of each gene product and 16S rRNA was shown below each figure.

*Comparison of antibody detection by MAT methods*

Blood from both virulent and avirulent groups were tested for antibody to *Leptospira*. The results were shown in Table 5. No antibody was detected in day 3 and day 7 samples from avirulent group. The high antibody titer was detected in samples from days 14 and 21. Two samples from day 5 and 3 from day 7 of virulent group gave positive antibody titer between 20-320.

Table 5 Comparison of MAT antibody titers between avirulent and virulent group

Avirulent group		Virulent Group	
Days post infection	MAT titer	Days post infection	MAT titer
3	<10	3	<10
3	<10	3	<10
3	<10	3	<10
7	<10	3	<10
7	<10	5	<10
7	<10	5	20
14	1280	5	<10
14	1280	5	40
14	1280	7	320
21	1280	7	320
21	1280	7	80
21	1280	7	<10

## DISCUSSION AND CONCLUSION

Golden Syrian Hamsters were used in this study since they demonstrate manifestations of the disease similar to those of severe human disease including interstitial nephritis, hemorrhage, and jaundice [28, 32-34]. It has been known that bacteria lose their ability to cause diseases in susceptible after being grown *in vitro*. In order to recover their ability to cause diseases, they must be injected into susceptible hosts and re-isolated again. In general, this process must be done for several times before the ability to cause diseases will be restored. At the beginning of this study, we planned to use the lost virulent *Leptospira* (which is called avirulent *Leptospira* in this study) to inject hamsters for several passages and observe the changes in hamsters pathologies. However, the work in animals cannot be done promptly and successfully. In addition, organisms could not be obtained enough for serial injection. Fortunately, Associate Professor Pattama Ekpo (Department of Immunology, Faculty of Medicine, Mahidol University) has the stock of virulent *Leptospira interrogans* serovar Pyrogenes and kindly provided these for our study. This isolate has been shown to induce manifestation in hamsters. Some part of the isolate was kept in liquid nitrogen and some was grown *in vitro*. We have found that the part that was grown *in vitro* for a while has lost the ability to induce sickness in hamsters. The animals survived at least 21 days post infection. In our pilot study, hamsters infected with the isolate kept in liquid nitrogen died around days 5-6 post infection. For this reason, we study changes in pathologies, cytokine and *Leptospira* gene expression in tissues obtained from these two groups of animals.

The difference of pathologies in two groups of hamsters was observed in this study. Cytokine gene expression was detected in kidneys, livers and lungs. The expression of LipL21, LipL32 and collagenase in those organs were demonstrated. In order to correlate cytokine and *Leptospira* gene expression with tissue pathologies, further experiments such as real-time PCR to quantitate amount of gene expression. In addition, *in situ* hybridization will be another useful technique for demonstrating whether the location of cytokine or *Leptospira* gene expression correlate to the region of tissues

where pathologies were observed. Finally, we obtained preliminary data that amount of LipL21, LipL32 and collagenase gene expression was relatively different. The genes which expression was different may be involved in pathogenesis and are good candidate for vaccine development. Since we used organisms left in stock for studying this part of work, further work should be done to confirm this part of observation.

The outputs of this project are as follows.

1. Scientific information for further studies on pathogenesis and vaccine development. Samples left from this project can be further used for other research questions.
2. Part of this project is a thesis of a student in the master degree program and a senior project of two undergraduate students.
3. A publication has obtained from this project, one manuscript has been submitted and at least two more manuscripts can be generated.
4. Some part of data from this project were presented by students in three scientific meetings.



สถาบันวิทยบริการ  
จุฬาลงกรณ์มหาวิทยาลัย

## REFERENCES

1. Dursun B, Bostan F, Artac M, Varan HI, Suleymanlar G. Severe pulmonary haemorrhage accompanying hepatorenal failure in fulminant leptospirosis. *Int J Clin Pract* 2007;61(1):164-7.
2. Palaniappan RU, Ramanujam S, Chang YF. Leptospirosis: pathogenesis, immunity, and diagnosis. *Curr Opin Infect Dis* 2007;20(3):284-92.
3. Sitprija V, Pipatanagul V, Mertowidjojo K, Boonpucknavig V, Boonpucknavig S. Pathogenesis of renal disease in leptospirosis: Clinical and experimental studies. *Kidney Int* 1980;17(6):827-36.
4. Cullen PA, Cordwell SJ, Bulach DM, Haake DA, Adler B. Global analysis of outer membrane proteins from *Leptospira interrogans* serovar Lai. *Infect Immun* 2002;70(5):2311-8.
5. Cullen PA, Haake DA, Bulach DM, Zuerner RL, Adler B. LipL21 is a novel surface-exposed lipoprotein of pathogenic *Leptospira* species. *Infect Immun* 2003;71(5):2414-21.
6. Lee SH, Kim S, Park SC, Kim MJ. Cytotoxic activities of *Leptospira interrogans* hemolysin SphH as a pore-forming protein on mammalian cells. *Infect Immun* 2002;70(1):315-22.
7. Matsunaga J, Barocchi MA, Croda J, *et al.* Pathogenic *Leptospira* species express surface-exposed proteins belonging to the bacterial immunoglobulin superfamily. *Mol Microbiol* 2003;49(4):929-45.
8. Nally JE, Chow E, Fishbein MC, Blanco DR, Lovett MA. Changes in lipopolysaccharide O antigen distinguish acute versus chronic *Leptospira interrogans* infections. *Infect Immun* 2005;73(6):3251-60.
9. Werts C, Tapping RI, Mathison JC, *et al.* Leptospiral lipopolysaccharide activates cells through a TLR2-dependent mechanism. *Nat Immunol* 2001;2(4):346-52.

10. de Fost M, Hartskeerl RA, Groenendijk MR, van der Poll T. Interleukin 12 in part regulates gamma interferon release in human whole blood stimulated with *Leptospira interrogans*. *Clin Diagn Lab Immunol* 2003;10(2):332-5.
11. Naiman BM, Alt D, Bolin CA, Zuerner R, Baldwin CL. Protective killed *Leptospira borgpetersenii* vaccine induces potent Th1 immunity comprising responses by CD4 and gammadelta T lymphocytes. *Infect Immun* 2001;69(12):7550-8.
12. Klimpel GR, Matthias MA, Vinetz JM. *Leptospira interrogans* activation of human peripheral blood mononuclear cells: preferential expansion of TCR gamma delta+ T cells vs TCR alpha beta+ T cells. *J Immunol* 2003;171(3):1447-55.
13. Vernel-Pauillac F, Merien F. Proinflammatory and immunomodulatory cytokine mRNA time course profiles in hamsters infected with a virulent variant of *Leptospira interrogans*. *Infect Immun* 2006;74(7):4172-9.
14. Diament D, Brunialti MK, Romero EC, Kallas EG, Salomao R. Peripheral blood mononuclear cell activation induced by *Leptospira interrogans* glycolipoprotein. *Infect Immun* 2002;70(4):1677-83.
15. Dorigatti F, Brunialti MK, Romero EC, Kallas EG, Salomao R. *Leptospira interrogans* activation of peripheral blood monocyte glycolipoprotein demonstrated in whole blood by the release of IL-6. *Braz J Med Biol Res* 2005;38(6):909-14.
16. Yang CW, Wu MS, Pan MJ, Hong JJ, Yu CC, Vandewalle A, Huang CC. *Leptospira* outer membrane protein activates NF-kappaB and downstream genes expressed in medullary thick ascending limb cells. *J Am Soc Nephrol* 2000;11(11):2017-26.
17. Lo M, Bulach DM, Powell DR, Haake DA, Matsunaga J, Paustian ML, Zuerner RL, Adler B. Effects of temperature on gene expression patterns in *Leptospira interrogans* serovar Lai as assessed by whole-genome microarrays. *Infect Immun* 2006;74(10):5848-59.
18. Azzurri A, Sow OY, Amedei A, *et al.* IFN-gamma-inducible protein 10 and pentraxin 3 plasma levels are tools for monitoring inflammation and disease activity in *Mycobacterium tuberculosis* infection. *Microbes Infect* 2005;7(1):1-8.

19. de Fost M, Chierakul W, Pimda K, Dondorp AM, White NJ, Van der Poll T. Activation of cytotoxic lymphocytes in patients with scrub typhus. *Am J Trop Med Hyg* 2005;72(4):465-7.
20. Eck M, Schmausser B, Scheller K, Toksoy A, Kraus M, Menzel T, Muller-Hermelink HK, Gillitzer R. CXC chemokines Gro(alpha)/IL-8 and IP-10/MIG in *Helicobacter pylori* gastritis. *Clin Exp Immunol* 2000;122(2):192-9.
21. Mihm S, Schweyer S, Ramadori G. Expression of the chemokine IP-10 correlates with the accumulation of hepatic IFN-gamma and IL-18 mRNA in chronic hepatitis C but not in hepatitis B. *J Med Virol* 2003;70(4):562-70.
22. De Fost M, Chierakul W, Limpaboon R, Dondorp A, White NJ, van Der Poll T. Release of granzymes and chemokines in Thai patients with leptospirosis. *Clin Microbiol Infect* 2007;13(4):433-6.
23. Hung CC, Chang CT, Chen KH, Tian YC, Wu MS, Pan MJ, Vandewalle A, Yang CW. Upregulation of chemokine CXCL1/KC by leptospiral membrane lipoprotein preparation in renal tubule epithelial cells. *Kidney Int* 2006;69(10):1814-22.
24. Yang CW, Hung CC, Wu MS, Tian YC, Chang CT, Pan MJ, Vandewalle A. Toll-like receptor 2 mediates early inflammation by leptospiral outer membrane proteins in proximal tubule cells. *Kidney Int* 2006;69(5):815-22.
25. Athanazio DA, Santos CS, Santos AC, McBride FW, Reis MG. Experimental infection in tumor necrosis factor alpha receptor, interferon gamma and interleukin 4 deficient mice by pathogenic *Leptospira interrogans*. *Acta Trop* 2008;105(1):95-8.
26. Gamberini M, Gomez RM, Atzingen MV, *et al.* Whole-genome analysis of *Leptospira interrogans* to identify potential vaccine candidates against leptospirosis. *FEMS Microbiol Lett* 2005;244(2):305-13.
27. Haake DA, Chao G, Zuerner RL, *et al.* The leptospiral major outer membrane protein LipL32 is a lipoprotein expressed during mammalian infection. *Infect Immun* 2000;68(4):2276-85.
28. Guerreiro H, Croda J, Flannery B, *et al.* Leptospiral proteins recognized during the humoral immune response to leptospirosis in humans. *Infect Immun* 2001;69(8):4958-68.



29. Boonyod D, Poovorawan Y, Bhattarakosol P, Chirathaworn C. LipL32, an outer membrane protein of *Leptospira*, as an antigen in a dipstick assay for diagnosis of leptospirosis. *Asian Pac J Allergy Immunol* 2005;23(2-3):133-41.
30. Fernandes CP, Seixas FK, Coutinho ML, *et al.* Monoclonal antibodies against LipL32, the major outer membrane protein of pathogenic *Leptospira*: production, characterization, and testing in diagnostic applications. *Hybridoma (Larchmt)* 2007;26(1):35-41.
31. Yang CW, Wu MS, Pan MJ, Hsieh WJ, Vandewalle A, Huang CC. The *Leptospira* outer membrane protein LipL32 induces tubulointerstitial nephritis-mediated gene expression in mouse proximal tubule cells. *J Am Soc Nephrol* 2002;13(8):2037-45.
32. Barnett JK, Barnett D, Bolin CA, Summers TA, Wagar EA, Cheville NF, Hartskeerl RA, Haake DA. Expression and distribution of leptospiral outer membrane components during renal infection of hamsters. *Infect Immun* 1999;67(2):853-61.
33. Haake DA, Mazel MK, McCoy AM, Milward F, Chao G, Matsunaga J, Wagar EA. Leptospiral outer membrane proteins OmpL1 and LipL41 exhibit synergistic immunoprotection. *Infect Immun* 1999;67(12):6572-82.
34. Praditpornsilpa K, Sangjun N, Kittikowit W, Phulsuksombati D, Avihingsanon Y, Kansanabuch T, Tungsanga K, Eiam-Ong S. Alleviation of renal and pulmonary injury by immunomodulation in leptospirosis: hamster model. *J Med Assoc Thai* 2006;89 Suppl 2:S178-87.