

Pigmented corneal mass: clue to diagnose of fungal corneal ulcer

Ngamjit Kasetsuwan*

Somboon Sophonthanaruk**

Kasetsuwan N, Sophonthanaruk S. Pigmented corneal mass: clue to diagnose of fungal corneal ulcer. Chula Med J 2004 Oct; 48(10): 679 - 85

A 56-year-old female was admitted to the Ophthalmology Unit of King Chulalongkorn Memorial Hospital; she presented with a painful, red, right eye after having sustained an injury from a rock. Examination of the right cornea by slit lamp showed a paracentral, discoid, brown to brownish-orange lesion with feathery border and deep infiltration. The lesion had epithelial defect and was approximately 3.0x3.5 mm² in size. Anterior chamber indicated reaction with cell and flare. Conjunctiva showed ciliary injection. The patient was diagnosed with fungal corneal ulceration and treated with topical anti-fungal medication. Surgical amniotic membrane transplantation was performed to treat persistent corneal epithelial defect. Consequently, the patient's signs and symptoms improved. Curvularia species which is pigmented fungi was identified by specimen culture. Previous retrospective study found that of 391 severe corneal ulcer cases admitted to King Chulalongkorn Memorial Hospital from January 1988 to December 2000, Curvularia spp. was identified as the cause of corneal ulceration in only 6 cases.

Keywords : Fungus, Pigmentation, Curvularia spp, Corneal ulcer.

Reprint request : Kasetsuwan N. Department of Ophthalmology, Faculty of Medicine,
Chulalongkorn University, Bangkok 10330, Thailand.

Received for publication. June 15, 2004.

* Department of Ophthalmology, Faculty of Medicine, Chulalongkorn University

** Sawangdaendin Hospital, Sakalnakorn

งามจิตต์ เกษตรสุวรรณ, สมบูรณ์ โสภณนารักษ์. ก้อนสีที่กระจกตา: ตัวช่วยสำหรับการวินิจฉัยแผลติดเชื้อราที่กระจกตา. จุฬาลงกรณ์เวชสาร 2547 ต.ค; 48(10): 679 – 85

รายงานผู้ป่วยหญิงไทยที่มารับการตรวจรักษาที่โรงพยาบาลจุฬาลงกรณ์ ด้วยเรื่องปวดตาแดงที่ตาขวาหลังจากได้รับอุบัติเหตุจากก้อนหิน การตรวจตาพบก้อนกลมสีน้ำตาลที่กระจกตา บริเวณตรงกลาง ขนาด 3.0x3.5 มม² มีขอบปุย ร่วมกับมีแผลไม่ปิดของผิวกระจกตา นอกจากนี้ ยังตรวจพบมีการอักเสบในช่องหน้าม่านตาและ เยื่อตาอักเสบร่วมด้วย ผู้ป่วยได้รับการวินิจฉัยว่าเป็นแผลติดเชื้อราที่กระจกตา ได้ให้การรักษาด้วยยาฆ่าเชื้อราชนิดหยอด ร่วมกับการผ่าตัดเยื่อหุ้มรกเพื่อปิดแผลของผิวกระจกตาเนื่องจากการล่าช้าของการปิดของผิวกระจกตาเกินกำหนด ภายหลังการรักษา ผู้ป่วยมีอาการและอาการแสดงทางตาดีขึ้น ผลตรวจและเพาะเชื้อทางห้องปฏิบัติการพบว่าเป็นเชื้อราชนิด *Curvularia* ซึ่งเป็นเชื้อราที่เป็นสาเหตุของการติดเชื้อที่กระจกตาไม่มากนัก จากการทบทวนการศึกษาในโรงพยาบาลจุฬาลงกรณ์ตั้งแต่ปี 2531-2543 พบว่าผู้ป่วยที่ได้รับการติดเชื้อที่กระจกตาอย่างรุนแรงมีจำนวน 391 ราย พบว่าเป็นเชื้อราชนิด *Curvularia* มีเพียง 6 รายเท่านั้น

คำสำคัญ : เชื้อรา, ก้อนสี, *Curvularia* spp, กระจกตาติดเชื้อ

สถาบันวิทยบริการ
จุฬาลงกรณ์มหาวิทยาลัย

The diagnosis of fungal keratitis can be difficult and is often delayed. Fungi from more than ten genera have been detected and isolated from cases of eye infection⁽¹⁾. One of the most unusual characteristics of fungal keratitis is pigmented corneal ulcer. The distinction between nonpigmented and pigmented keratomycoses is not commonly possible in clinical examination. Consequently, the treatment will be inappropriate or delayed, causing progressive infection and finally more tissue destruction. The diagnosis and treatment of fungal keratitis continue to be a challenge for ophthalmologists. *Curvularia* species is a saprophytic dark pigmented fungus that resides primarily in soil. Reports of human disease caused by this organism are rare but they include: endocarditis, brain abscess, skin infection, onychomycosis, pneumonia, disseminated disease, mycetoma, allergic bronchopulmonary disease, sinusitis and keratitis.⁽²⁾ The rarity of keratitis caused by member of genus *Curvularia* has been reviewed in this report.

Case report

A 56 – year – old Thai female attended the Ophthalmology Unit, King Chulalongkorn Memorial Hospital on November 30, 2000. She complained of a painful, red, right eye for ten days. Two weeks earlier, she had an accident to the right eye from a stone while gardening. One week later, she instilled a combination of antibiotic and corticosteroid eye drop which she bought at a pharmacy for a few days. Slit lamp examination revealed a severely inflamed eye with profuse mucopurulent discharge. The right cornea showed a paracentral, raised, discoid, brown to brownish – orange lesion with feathery appearing infiltrate and irregular border. The infiltration was measured 3.5 mm horizontally and 3.0 mm vertically in diameter, with an overlying epithelial defect measuring approximately 4.0 mm by 4.2 mm in diameter (Figure 1, 2). There was moderate iritis but the fundus appeared normal. The visual acuity in her right eye was 1 ft of finger counting. Under topical anesthesia, the entire lesion including the edge was

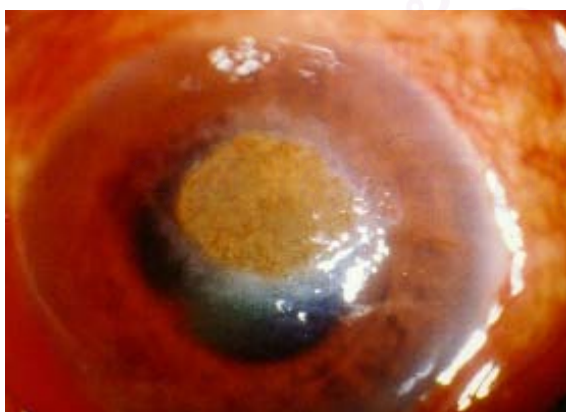


Figure 1. Pigmented corneal mass.

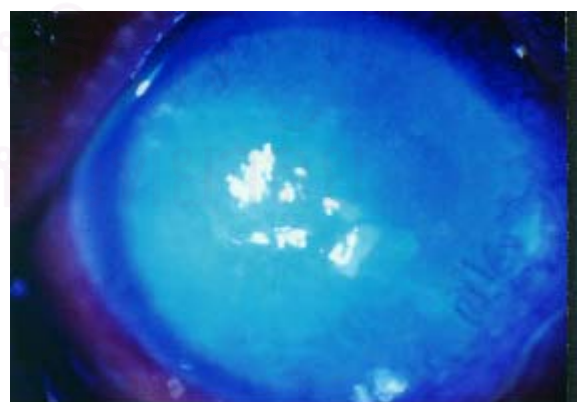


Figure 2. Pigmented corneal mass stained with fluorescence.

scraped and sent to laboratory for microorganism identification. The material obtained from eye scrapping was examined under microscope with 10 % KOH and Gram's stain. It revealed a large amount of septate hyphae. The rest of the material were inoculated on standard plates and broth: blood, chocolate and Sabouraud's dextrose agar plate and thioglycolate broth. On Sabouraud's dextrose agar plate, they produced a grayish – black colony with numerous thick – walled, septate mycelium. The isolate was tentatively identified as a member of the genus *Curvularia*. Her treatment was started with atropine eye drop twice daily, Fluconazole 2 % and topical Amphotericin B instilled every 1 hour, Garamycin forte eye drop was also used 4 times a day and tear lubrication every 2 hours. Ocular examination under slit-lamp biomicroscopy was done every day to evaluate the improvement or progression. Until 3 weeks later, her ocular symptoms and signs gradually improved with the same medications. The eye was free of conjunctival discharge but ciliary injection was present. The right cornea appeared stable but the pigmentation was still on the surface with corneal epithelial defect. We started intensive treatment of the problem of corneal epithelial defect by decreasing both antifungal drops to 4 times a day and topical antibiotic was discontinued. The standard conventional treatment was continued for another month by increasing the frequency of lubrication, both with eye drop and gel. The punctual occlusion was also performed but the defect persisted. We decided to use human amniotic membrane transplanted on the surface of the defect after scraping off the pigment. After amniotic membrane transplantation, epithelialization was detected by fluorescence in

staining and the epithelial defect healed within 4 weeks.

Discussion

The incidence of fungal keratitis is high in the tropical and subtropical regions and is related to climatic conditions and agricultural population. In these regions, including Thailand⁽³⁾, predominantly filamentous fungi rather than yeasts cause fungal keratitis. More than 70 species belonging to 40 genera have been reported as causes of keratitis.⁽⁴⁾ Even though Wood and Kaufman summarized many of the typical physical findings of fungal keratitis which include elevated dry infiltrate with feathery hyphate edges, satellite lesions, immune rings, and endothelial plaque,^(7,20) the diagnosis and treatment of fungal keratitis still remain a challenge in the field of ophthalmology. The diagnosis is sometime difficult and easily confused with other microorganism which often causes delay or improper in treatment, resulting in devastation and poor visual outcome. Moreover, the distinction between non-pigmented and pigmented fungi is not commonly possible in clinical examination.

Although ocular mycoses due to saprophytic fungus are rather infrequent, the use of antibiotics and steroid may be risk factors for their implantation and growth in the eye, particularly after trauma. Haggerty and Zimmerman⁽⁶⁾ have presented evidence of the increasing incidence of ocular mycosis since the introduction of corticosteroids. In the analysis of the material from perforated ulcers and post traumatic vitreous abscess at the Armed Forces, they found that before the introduction of corticosteroid, fungi were implicated in only 1 in every 11329 eyes. After the use of corticosteroid, however, it has become

almost universal. The incidence has increased to 1 in 777 in such cases. It should be realized that some saprophytic fungi have a latent pathogenic capacity. When a host's resistance to infection is lowered by chronic disease, steroid, antibiotics or injury, some saprophytic fungi are able to invade ocular tissues and induce pathogenic changes.⁽⁷⁾ Our patient also had previous history of trauma and corticosteroid use; these evidences support the report.

Fusarium spp. is the most frequent etiological agent and has been reported in up to 65 % of fungal keratitis. *Aspergillus spp.* and *Candida albicans* are also common, while *Curvularia* species occur less often.^(8-10,14) A previous retrospective study found that of 391 severe degree corneal ulcer cases admitted at King Chulalongkorn Memorial Hospital, the incidence of fungal corneal ulcer occurred mostly in the old age group (51 – 70 yrs , 43.3 %). *Curvularia* species were identified in only 6 cases of the series. The most common predisposing factors of fungal corneal ulcer were unknown, while ocular trauma from several materials during agricultural process was found to be the most frequently known predisposing factor. This may be due to the fact that the majority of Thai people are agricultural workers, which is similar to the patient reported here. *Curvularia spp.* commonly occur as contaminants,^(11,12) being saprophytic pigmented fungi found in soil and air,^(1-2,8,13-14) as well as on plant.^(1,2) It had been previously considered nonpathogenic or thought to affect humans only rarely, but these fungi are now being increasingly reported to cause human diseases. The genus *Curvularia* comprises about 30 species; only seven of them have been involved in human infections. The most commonly recovered species in man have been *C. lunata* and *C.*

geniculata.⁽¹⁵⁻¹⁷⁾ *Curvularia spp.* have a brown septate mycelium 2 – 5 um in diameter, with characteristic four – cell conidia. On Sabouraud's dextrose agar, they produce a flat, velvety brown – black colony that correlates well with the clinical pigmentation seen on biomicroscopy in our patient.

The management of *Curvularia* keratitis has sometimes been successfully treated with topical amphotericin B and pimaricin 5 % solution;^(8,18-19) it usually involves surgical treatment such as corneal transplantation. Although we found that corneal infiltration in our patient was almost completely controlled, evidenced by improved patient's symptoms and signs, a problem occurred ; persistent corneal epithelial defect which appears one of the most frequent complications in keratomycosis.⁽¹²⁾ The defect did not heal by conventional treatment for a month. We used amniotic membrane transplantation to promote healing as reported by Kim and Tseng⁽²¹⁾ in 1995 that they developed the method of using preserved amniotic membrane for ocular reconstruction. In 1997, Lee and Tseng⁽²²⁾ reported a successful and long-term stability of corneal re-epithelialization of persistent corneal epithelial defect after various conditions by covering the defect with a layer of human amniotic membrane. The advantages of amniotic membrane are mainly derived from its basement membrane and avascular stroma matrix. While basement membrane facilitates migration of the epithelial cells,⁽²³⁾ it also reinforces the adhesion of basal epithelial cells,^(24,25) and promotes epithelial differentiation;^(26,27) its avascular stroma also contains a high concentration of basic fibroblast growth factor, basement membrane components, and unknown trophic factors such as

proteinase inhibitors. Also, it has the ability to exclude inflammatory cells as shown in the study of Kim JS⁽²⁸⁾ and his coworkers. These effects would directly and indirectly modulate the inflammatory process induced by infection, and they also explain why the amniotic membrane effectively permits rapid epithelialization. Our management for this patient and the result support the finding, therefore amniotic membrane transplantation is considered an alternative method rather than tissue adhesive, lamellar or penetrating keratoplasty for the treatment of persistent corneal epithelial defects with sterile ulceration that are refractory to conventional medical treatment.

In conclusion, fungal infections are frequently diagnosed late. They also have variable responses to the existing antifungal therapy. Any additional clinical clues to the recognition of this infection would be helpful. This report is intended to alert ophthalmologists to the infrequent keratitis. An attention to the clinical presentation is a potentially helpful sign in the detection of pigmented fungal corneal ulcer.

References

1. Nityanada K, Sivasubramaniam P, Ajello L. A case of mycotic keratitis caused by *geniculata*. *Arch Ophthalmol* 1964 Apr; 71: 456 - 8
2. Rinaldi MG, Phillips P, Schwartz JG, Winn RE, Holt GR, Shagets FW, Elrod J, Nishioka G, Aufdemorte TB. Human *Curvularia* infections; Report of five cases and review of the literature. *Diagn Microbiol Infect Dis* 1987 Jan; 6(1): 27 - 39
3. Boonpasart S, Kasetuwan N, Puangsrichareon V, Pariyakanok L, Jittpoonkusol T. Infectious keratitis at King Chulalongkorn Memorial Hospital: a 12-year retrospective study of 391 cases. *J Med Assoc Thai* 2002 Jun; 85 Suppl 1: S217 - 30
4. Thomas PA. Mycotic keratitis: an underestimated mycosis. *J Med Vet Mycol* 1994; 32: 235 - 6
5. Kaufman HE, Wood RM. Mycotic keratitis. *Am J Ophthalmol* 1965 Jun; 59: 993 - 1000
6. Haggerty TE, Zimmerman LE. Mycotic keratitis. *South Med J* 1958 Feb; 51(2): 153 - 9
7. Ley AP. Experimental fungus infections of cornea; a preliminary report. *Am J Ophthalmol* 1956 Oct; 42(4 Part 2): 59 - 71
8. Forster RK, Rebell G. The diagnosis and management of keratomycosis. I. Cause and diagnosis. *Arch Ophthalmol* 1975 Oct; 93(10): 957 - 8
9. Rosa RH Jr, Miller D, Alfonso EC. The changing spectrum of fungal keratitis in south Florida. *Ophthalmology* 1994 Jun; 101(6): 1005 - 13
10. McDonnell PJ, Green WR. Keratitis. In: Mandell GL, Douglas RG, Bennett JE, eds. *Principles and Practice Infectious Disease*, 3rd ed. New York : Churchill Livingstone, 1990: 981 - 7
11. Upadhyay MP, Karmacharya PC, Koirala S, Tuladhar NR, Bryan LE, Smolin G, Whicher JP. Epidemiologic characteristics, predisposing factors, and etiologic diagnosis of corneal ulceration in Nepal. *Am J Ophthalmol* 1991 Jan 15; 111(1): 92 - 9
12. Wind CA, Polack FM. Keratomycosis due to *Curvularia lunata*. *Arch Ophthalmol* 1970 Nov; 84(5): 694 - 6
13. Bartynski JM, McCaffery TV, Frigas E. Allergic fungal sinusitis secondary to dematiaceous

- fungi — *Curvularia lunata* and *Alternaria*.
Otolaryngology Head Neck Surg 1990 Jul;
103(1): 32 - 9
14. Killingsworth SM, Wetmore SJ. *Curvularia* /
Drechslera sinusitis. *Laryngoscope* 1990 Sep;
100(9): 932 - 7
15. Anaissie EJ, Bodey GP, Rinaldi MG. Emerging
fungal pathogens. *Eur J Clin Microbiol Infect*
Dis 1989 Apr; 8(4):323 - 30
16. Mc Ginins MR. Dematiaceous fungi. In: Lemmette
EH, ed. *Manual of Clinical Microbiology* 4th
ed. Washington DC: American Society for
Microbiology. 1985: 563 - 9
17. Kaufman SM. *Curvularia* endocarditis following
cardiac surgery. *Am J Clin Pathol* 1971 Oct;
56(4): 466 - 70
18. O'Day DM. Selection of appropriate antifungal
therapy. *Cornea* 1987; 6(4): 238 - 45
19. Dorey SE, Ayliffe WH, Edrich C, Barrie D, Fison
P. Fungal keratitis caused by *Curvularia*
lunata, with successful medical treatment.
Eye 1997; 11(Pt 5): 754 - 5
20. Berger ST, Katsev DA, Mondino BJ, Pettit TH.
Macroscopic pigmentation in a dematiaceous
fungal keratitis. *Cornea* 1991 May;10(3):
272 - 6
21. Kim JC, Tseng SC. Transplantation of preserved
human amniotic membrane for surface
reconstruction in severely damaged rabbit
corneas. *Cornea* 1995 Sep;14(5):473 - 84
22. Lee SH, Tseng SC. Amniotic membrane trans-
plantation for persistent epithelial defects
with ulceration. *Am J Ophthalmol* 1997 Mar;
123(3): 303 - 12
23. Terranova VP, Lyall RM. Chemotaxis of human
gingival epithelial cells to laminin. A
mechanism for epithelial cell apical migration.
J Periodontol 1986 May; 57(5): 311 - 7
24. Khodadoust AA, Silverstein AM, Kenyon DR,
Dowling JE. Adhesion of regenerating corneal
epithelium. The role of basement membrane.
Am J Ophthalmol 1968 Mar; 65(3): 339 - 48
25. Sonnenberg A, Calafat J, Janssen H, Daams H,
van der Raaij-Helmer LM, Falcioni R, Kennel
SJ, Aplin JD, Baker J, Loizidou M, et al.
Integrin alpha 6/beta 4 complex is located
in hemidesmosomes, suggesting a major
role in epidermal cell-basement membrane
adhesion. *J Cell Biol* 1991 May;113(4):
907 - 17
26. Streuli CH, Bailey N, Bissell MJ. Control of
mammary epithelial differentiation: basement
membrane induces tissue-specific gene
expression in the absence of cell-cell
interaction and morphological polarity. *J Cell*
Biol 1991Dec;115(5):1383 - 95
27. Kurpakus MA, Stock EL, Jones JC. The role of
the basement membrane in differential
expression of keratin proteins in epithelial
cells. *Dev Biol* 1992 Apr;150(2): 243 - 55
28. Kim JS, Kim JC, Hahn TW, Park WC. Amniotic
membrane transplantation in infectious
corneal ulcer. *Cornea* 2001Oct; 20(7): 720 - 6