

Treatment of pediatric intussusception by pneumatic reduction under ultrasound guidance: first case of King Chulalongkorn Memorial Hospital

Atchara Mahayosnond *

Ekpol Sethsakul*

Panruethai Trinavarat*

Sudee Chomdej*

Somboon Roekwibunsi**

Mahayosnond A, Sethsakul E, Trinavarat P, Chomdej S, Roekwibunsi S. Treatment of pediatric intussusception by pneumatic reduction under ultrasound guidance : first case of King Chulalongkorn Memorial Hospital. Chula Med J 2004 May; 48(5): 299 - 307

Pneumatic or air enema under ultrasound guidance is the most recently developed technique for non-surgical treatment of pediatric intussusception with obvious advantage of radiation-free. The first case of King Chulalongkorn Memorial Hospital who was successfully treated for uncomplicated ileocolic intussusception by this technique is hereby reported. The clinical history, methods for diagnosis and non-surgical reduction techniques of the disease are reviewed.

Keywords : *Intussusception, Pneumatic reduction, Ultrasound guidance.*

Reprint request : Mahayosnond A. Department of Radiology, Faculty of Medicine,
Chulalongkorn University, Bangkok 10330, Thailand

Received for publication : January 15, 2004.

* Department of Radiology, Faculty of Medicine, Chulalongkorn University

** Department of Surgery, Faculty of Medicine, Chulalongkorn University

อัจฉรา มหายศนันท์, เอกพล เศรษฐ์สกุล, ปานฤทัย ตรีนวรัตน์, สุดี ชมเดช, สมบูรณ์ ฤกษ์วิบูลย์ศรี. การรักษาโรคลำไส้กลืนกันด้วยวิธีสวนทวารหนักด้วยลม โดยสังเกตด้วยอัลตราโซโนกราฟี : รายงานผู้ป่วยรายแรกในโรงพยาบาลจุฬาลงกรณ์. จุฬาลงกรณ์เวชสาร 2547 พ.ศ; 48(5) : 299 – 308

การสวนลำไส้ด้วยลมโดยสังเกตด้วยอัลตราโซโนกราฟีเป็นวิธีรักษาโรคลำไส้กลืนกันในผู้ป่วยเด็กโดยไม่ผ่าตัดที่ได้รับการพัฒนามาล่าสุดและมีข้อดีที่เด่นชัดคือการใช้เอกเรย์ รายงานนี้เป็นเด็กโรคลำไส้กลืนกันรายแรกในโรงพยาบาลจุฬาลงกรณ์ที่ได้รับการรักษาด้วยวิธีนี้และประสบผลสำเร็จ ผู้ศึกษาได้ทบทวนวรรณกรรมและรายงานไว้ ณ. ที่นี้

คำสำคัญ : ลำไส้กลืนกัน, สวนทวารหนักด้วยลม, อัลตราโซโนกราฟี

สถาบันวิทยบริการ
จุฬาลงกรณ์มหาวิทยาลัย

Intussusception is a common abdominal emergency in infants and children, but there is considerable variability concerning its diagnosis and treatment. The current non-surgical management of ileocolic intussusception includes hydrostatic and pneumatic reduction, both are performed under fluoroscopic guidance. Pneumatic reduction with fluoroscopic guidance is claimed to be quick, safe and clean, and it has also been reported to have high success rates.⁽¹⁻⁴⁾ However, fluoroscopy uses ionizing radiation, and it may not detect lead points and residual ileoileal intussusception.⁽⁵⁾ Recently, ultrasound guided hydrostatic reduction has strongly been recommended because it has no radiation exposure, and it can be used to confirm the presence of intussusception and subsequent reduction.⁽⁶⁻¹⁰⁾ Ultrasound guided hydrostatic reduction can detect lead points and residual ileoileal intussusception more readily than fluoroscopy guided pneumatic reduction. However, the most recently developed technique of non-surgical treatment of intussusception, pneumatic reduction under ultrasound guidance has combined the advantages of high success rate with pneumatic reduction and radiation-free of the ultrasound guidance. Herein, we report our first case of uncomplicated ileocolic intussusception who was successfully treated by pneumatic reduction under ultrasound guidance.

Case report

A 9-month-old boy was sent to the hospital with acute onset of colicky pain and vomiting for one day. The infant also had bloody mucous stool prior to admission. On physical examination, a mass was palpable at the right upper quadrant of his abdomen. The infant looked active with intermittent crying. A plain

radiograph of the abdomen revealed a soft tissue mass in the right upper quadrant with air outlining medially, the so-called meniscus sign (Figure 1). Findings on the radiograph characterized ileocolic intussusception. There was no evidence of free air which is the absolute contraindication for non-surgical treatment of intussusception. Ultrasonography was subsequently performed for definite diagnosis and evaluation of the presence of leading point. The palpable mass at the physical examination was found to be in the same location as that on the plain radiograph and it was proved by ultrasound as ileocolic intussusception. Its size was about 5 cm with multiple concentric rings of mixed hypo- and hyperechogenicity. On

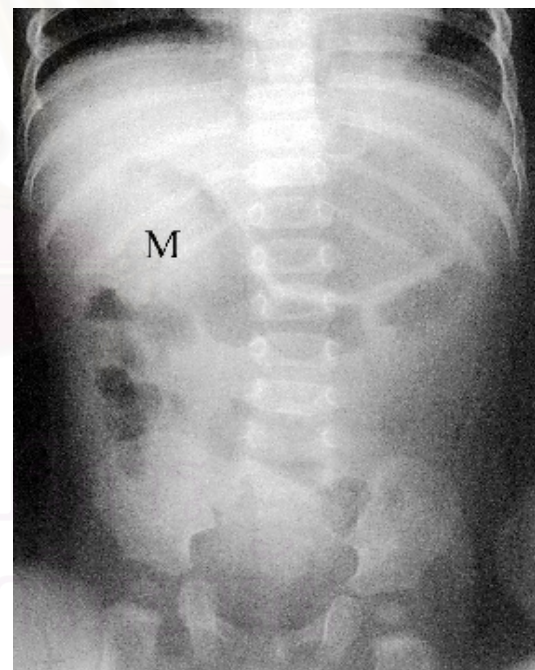


Figure 1. Plain radiograph of abdomen showed soft tissue mass (M) in right upper quadrant with colonic gas outlining medially, the so-call meniscus sign which is characteristic for the ileocolic intussusception.

cross-sectional ultrasound, finding of “Crescent-in-Doughnut” which is the characteristic of intussusception was demonstrated (Figure 2). There was no identifiable pathologic leading point or free fluid.

Based on an agreement with pediatric surgeons, the infant was diagnosed with uncomplicated ileocolic intussusception and he was then suitable for

non-surgical treatment. Pneumatic or air enema under ultrasound guidance was selected as the method for non-surgical reduction. The procedure was performed with pediatric surgeons stand by. Before starting the reduction, the infant was sedated with chloral hydrate for relaxation. Simple device for pneumatic reduction was used (Figure 3).

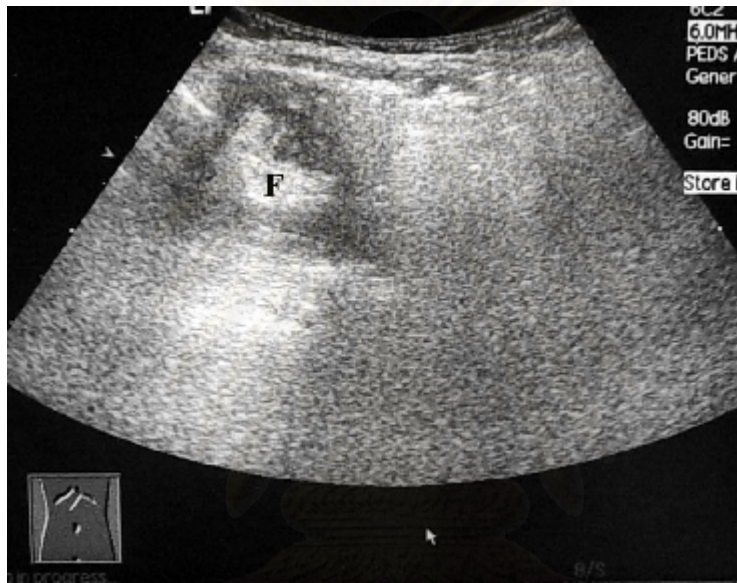

Figure 2. Cross sectional sonography of the mass showed hypoechoic mass with crescentic hyperechoic representing mesenteric fat inside (F). These findings are also characteristic for the intussusception.



Figure 3. Figure on the left is device used for pneumatic reduction. Bulb syringe and manometer are connected proximal to Y-shaped connector. (right figure)

A balloon catheter connected with the pneumatic reduction device was inserted into the infant's rectum. The balloon was inflated with 20 ml of air to prevent air leakage from the rectum during reduction. The mass of intussusception was continuously observed under real-time ultrasound during air pumping. Our ultrasound machine was Acuson Sequoia 512. We used 6.5 MHz convex probe with wide footprint which provided a large field of view. The pressure of air pushed into the rectum was controlled and observed under manometer connected with the device. The level of maximum pressure limit which is 120 mm Hg was marked with an easily recognized red sticker for safety. An 18-gauge needle was available at bedside for immediate abdominal decompression if there was an unexpected bowel

perforation or tension pneumoperitoneum. The applied air pressure in this case was only about 70 mm Hg. There was rapid reduction with backward movement of the intussusception and increased air echo in the colon. The characteristic ultrasound of intussusception disappeared within about 10 seconds after starting the air pump. There was diffuse air echo in the small bowel and loss of the palpable mass (Figure 4). The infant immediately stopped crying and burp. A plain radiograph of abdomen was finally performed to confirm complete reduction. The radiograph showed generalized air-filled bowel and disappearance of the mass (Figure 5). The infant was observed for 24 hours before discharge. There was clinical improvement without complication or recurrent of disease.

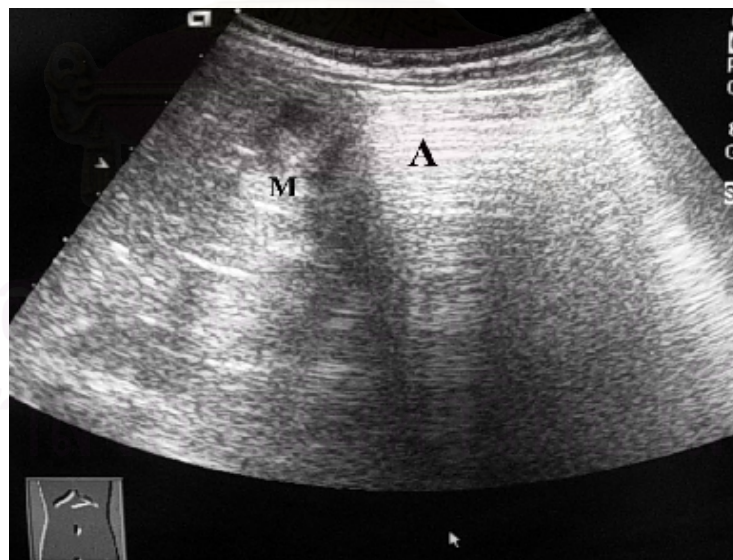

Figure 4. Image performed during pneumatic reduction showed backward movement of the intussusceptum (M) with increased air echo in the colon. (A)

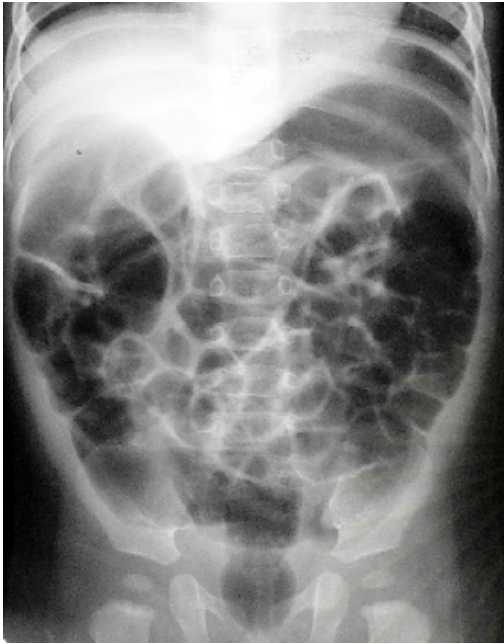


Figure 5. Plain radiograph of abdomen confirmed the complete reduction with loss of mass. There is generalized air-filled bowel.

Discussion

Intussusception is a common abdominal emergency of early childhood. About 90 % of cases are idiopathic, probably associated with hypertrophy of lymphoid tissue secondary to viral infection. Most of the pediatric intussusceptions are ileocolic type. The classic clinical triad of abdominal pain, palpable mass and red currant jelly stool are present in only less than 50 % of the cases, so that clinical diagnosis is sometime difficult.⁽¹¹⁾ Plain radiograph of the abdomen is commonly performed as an initial investigation of acute abdominal condition especially when the clinical diagnosis is uncertain. Unfortunately, it identifies intussusception in only about 50 %.⁽¹²⁾ It is now widely accepted that ultrasound is the modality of choice for diagnosis or excluding the presence of intussusception with 100 % accuracy when performed by well trained radiologists.⁽¹³⁻¹⁵⁾ When used

appropriately, a negative ultrasound thus obviates the unnecessary diagnostic enemas, and the use of the enema can then be limited to therapeutic purpose. Despite advances in anesthesia and success achieved with surgical reduction, the non-surgical enema technique of intussusception reduction has major advantages of reducing invasiveness, morbidity, costs and length of hospital stay. Anesthesia and surgery are not without risks, and handling of the bowel during attempted manual reduction may also tear the serosa and mucosa. The aim of enema reduction technique is, therefore, to obviate the need for surgery in the greatest number of children with intussusception as possible. However, if the patient has profound hypovolemic shock, peritonitis, or perforation, the child should be taken directly to the operating room. Two major techniques of non-surgical treatment of intussusception that are widely accepted and have been used throughout the world are hydrostatic reduction with barium enema and pneumatic reduction with air enema, both of which are under fluoroscopic observation. The pneumatic reduction technique was developed later than barium enema reduction with first reported cases from Argentina and China in 1959 and 1964, respectively.^(16,17) Since 1980s, pneumatic reduction has been increasingly used in the western countries, initially under guidance of radiologists from China.^(18,19) Air enema under fluoroscopic guidance has been shown to have some advantages over barium enema. Reports from institutions have shown that air enema is quicker, less messy, easily perform and therefore delivers less radiation to the patients.^(3, 18-21) Each report has also shown an increased reduction rate with air technique relative to barium. The largest number of patients treated with air enema was in a

study from China in 1986, including 6,396 pneumatic reductions with success rate of 95.25 % and perforation rate of only 0.14 %.⁽²²⁾ In a review of literature in 1992, Stinger et al. found that reduction rates with hydrostatic techniques from 1980 to 1991 were 50-78 %, whereas the success rate with pneumatic reduction from 1986 to 1991 was between 75 % and 94 %.⁽²¹⁾ At our hospital, we have started using pneumatic enema under fluoroscopy for non-surgical reduction of pediatric intussusception since 2001. There have been only a few cases treated with this technique but all reductions were successful. Barium enema is still used in our hospital but only by general radiologists at night-time when pediatric radiologist was not available. Because we have very small number of cases in the early phase since the beginning of pneumatic reduction at our hospital, statistic comparison of success rates between techniques is not possible.

Although pneumatic reduction under fluoroscopic guidance seems to be better than barium enema, it still needs ionizing radiation. In order to avoid radiation exposure, hydrostatic enema using water or saline solution under ultrasound guidance was performed in many parts of the world. This technique was first described by Kim et al. in 1982.⁽⁸⁾ The reported success rates of hydrostatic reduction under ultrasound guidance were between 80 % and 95.5 %.⁽²³⁻²⁶⁾ The highest success rate was reported from China in the study of Wang et al. with 377 reductions.⁽²⁷⁾ It was the study of Hadidi in 1999 that compared success rates of three techniques: air enema, barium enema and saline enema under ultrasound guidance with the results of 90 %, 70 % and 60 %, respectively.⁽²⁸⁾ Although high success rate of 95.5 % has been reported, this technique of reduction is still not a therapeutic modality familiar worldwide.

We have never performed saline enema at our hospital but we started the recently developed technique, pneumatic enema reduction under ultrasound guidance: the first case presented in this report. By reviewing the studies on hydrostatic enema reductions, we noted that the height of fluid reservoir must be adjusted to achieve the adequate pressure for pushing the intussusception backward. Fluid height of up to 5.75 feet which is equal to 120 mmHg in several difficult cases have been recorded in the study of Seong Ku Woo, et al.⁽²⁹⁾ Because of the smaller molecular weight of water and saline, the reservoirs containing these fluid have to be placed higher than that of barium.⁽³⁰⁾ It might be easier to control air pressure by observing the manometer than changing height of fluid reservoir. Pneumatic reduction under ultrasound guidance has both advantages of non-radiation technique and less messy of air enema. In 1990, Todani et al. reported from Japan 90.6 % success rate in 127 intussusceptions treated by this technique under strict indications and sedation with diazepam.⁽³¹⁾ There were also a study in China on this technique by Wang et al. in 1995 and Gu et al. in 2000 with success rates of 96.9 % in 217 cases and 95 % in 199 cases, respectively.^(32,33) A report from Korea by Yoon et al. in 2001 also shows high success rate of 92 % in 152 intussusceptions with 2 perforations.⁽¹⁰⁾

The highest success rate of 100 % was reported from Spain by Rubi et al. in 2002, but the number of the cases was only 21.⁽³⁴⁾

Conclusion

Pneumatic or air enema reduction under ultrasound guidance is now increasingly accepted as one of the non-surgical treatments of pediatric

intussusception with obvious advantages of radiation-free technique and high success rate. We also have successful outcome for our first case treated by this technique. We need more cases and experience for evaluation of the success rates, complication and overall outcome, comparing to barium enema and pneumatic enema under fluoroscopy.

References

1. Guo JZ, Ma XY, Zhou QH. Results of air pressure enema reduction of intussusception: 6,396 cases in 13 years. *J Pediatr Surg* 1986 Dec; 21(12): 1201 - 3
2. Kirks DR. Air intussusception reduction: "the winds of change". *Pediatr Radiol* 1995;25(2): 89-91
3. Shiels WE 2nd, Maves CK, Hedlund GL, Kirks DR. Air enema for diagnosis and reduction of intussusception: clinical experience and pressure correlates. *Radiology* 1991 Oct; 181(1): 169 - 72
4. Stein M, Alton DJ, Daneman A. Pneumatic reduction of intussusception: 5-year experience. *Radiology* 1992 Jun;183(3): 681 - 4
5. Miller SF, Landes AB, Dautenhahn LW, Pereira JK, Connolly BL, Babyn PS, Alton DJ, Daneman A. Intussusception: ability of fluoroscopic images obtained during air enemas to depict lead points and other abnormalities. *Radiology* 1995 Nov; 197(2): 493 - 6
6. Peh WC, Khong PL, Lam C, Chan KL, Cheng W, Lam WW, Saing H, Leong LL, Low LC, Tam PK. Reduction of intussusception in children using sonographic guidance. *AJR Am J Roentgenol* 1999 Oct;173(4): 985 - 8
7. Wood SK, Kim JS, Suh SJ, Paik TW, Choi SO. Childhood intussusception: US-guided hydrostatic reduction. *Radiology* 1992 Jan; 182(1): 77 - 80
8. Kim YG, Choi BI, Yeon KM, Kim CW. Diagnosis and treatment of childhood intussusception using real-time ultrasonography and saline enema: preliminary report. *J Korean Soc Med Ultrasound* 1982;1: 66 - 70
9. Bolia AA. Diagnosis and hydrostatic reduction of an intussusception under ultrasound guidance. *Clin Radiol* 1985 Nov; 36(6): 655 - 7
10. Yoon CH, Kin HS. Ultrasound guided reduction of childhood intussusception. *J Korean Radiol Soc* 1986; 22: 788 - 793
11. Daneman A, Alton DJ. Intussusception. Issues and controversies related to diagnosis and reduction. *Radiol Clin North Am* 1996 Jul;34(4): 743 - 56
12. Bolin H. Conventional roentgenography in diagnosis of intussusception in children. *Acta Radiol Diagn* 1964; 2 :32 - 40
13. Pracros JP, Tran-Minh VA, Morin de Finfe CH, Deffrenne-Pracros P, Louis D, Basset T. Acute intestinal intussusception in children. Contribution of ultrasonography (145 cases). *Ann Radiol (Paris)* 1987; 30(7): 525 - 30
14. Lim HK, Bae SH, Lee KH, Seo GS, Yoon GS. Assessment of reducibility of ileocolic intussusception in children: usefulness of color Doppler sonography. *Radiology* 1994 Jun; 191(3): 781 - 5
15. Verschelden P, Filiatrault D, Garel L, Grignon A, Perreault G, Boisvert J, Dubois J. Intussusception in children: reliability of US in diagnosis—a prospective study. *Radiology* 1992 Sep; 184(3): 741 - 4
16. Fiorito ES, Recalde Cuestas LA. Diagnosis and treatment of acute intestinal intussusception with controlled insufflation of air. *Pediatrics*

- 1959 Aug; 24(2): 241 - 4
17. Sheh YH, Ting WH, Yeh HH. Reduction of intestinal intussusception in infancy by colonic air insufflation. *Chin Med J (Engl)* 1964 Oct;83: 668 - 73
18. Gu L, Alton DJ, Daneman A, Stringer DA, Liu P, Wilmot DM, Reilly BJ. John Caffey Award. Intussusception reduction in children by rectal insufflation of air. *AJR Am J Roentgenol* 1988 Jun; 150(6): 1345 - 8
19. Phelan E, de Campo JF, Malecky G. Comparison of oxygen and barium reduction of ileocolic intussusception. *AJR Am J Roentgenol* 1988 Jun;150(6):1349 - 52
20. Miles SG, Cumming WA, Williams JL. Pneumatic reduction of ileocolic intussusception in children. *Pediatr Radiol* 1988;18(1): 3 - 5
21. Stringer MD, Pablot SM, Brereton RJ. Paediatric intussusception. *Br J Surg* 1992 Sep; 79(9): 867 - 76
22. Guo JZ, Ma XY, Zhou QH. Results of air pressure enema reduction of intussusception: 6,396 cases in 13 years. *J Pediatr Surg* 1986 Dec; 21(12): 1201 - 3
23. Gonzalez-Spinola J, Del Pozo G, Tejedor D, Blanco A. Intussusception: the accuracy of ultrasound-guided saline enema and the usefulness of a delayed attempt at reduction. *J Pediatr Surg* 1999 Jun;34(6):1016-20
24. Chiu CY, Tok TS. Intussusception reduction by hydrostatic saline enema under sonographical guidance: clinical experience in 33 cases. *J Formos Med Assoc* 1993 Jan; 92(1): 50 - 4
25. Rohrschneider WK, Troger J. Hydrostatic reduction of intussusception under US guidance. *Pediatr Radiol* 1995; 25(7): 530 - 4
26. Soun DS, Choy PC, Tok TS, Chiu CY. Reduction of intussusception by ultrasound-guided saline enema. *Zhonghua Min Guo Xiao Er Ke Yi Xue Hui Za Zhi* 1996 Jul-Aug; 37(4): 257 - 62
27. Wang GD, Liu SJ. Enema reduction of intussusception by hydrostatic pressure under ultrasound guidance: a report of 377 cases. *J Pediatr Surg* 1988 Sep; 23(9): 814 - 8
28. Hadidi AT, El Shal N. Childhood intussusception: a comparative study of nonsurgical management. *J Pediatr Surg* 1999 Feb; 34(2): 304 - 7
29. Wood SK, Kim JS, Suh SJ, Paik TW, Choi SO. Childhood intussusception: US-guided hydrostatic reduction. *Radiology* 1992 Jan; 182(1): 77 - 80
30. Kuta AJ, Benator RM. Intussusception: hydrostatic pressure equivalents for barium and meglumine sodium diatrizoate. *Radiology* 1990 Apr; 175(1): 125 - 6
31. Todani T, Sato Y, Watanabe Y, Toki A, Uemura S, Urushihara N. Air reduction for intussusception in infancy and childhood: ultrasonographic diagnosis and management without X-ray exposure. *Z Kinderchir* 1990 Aug;45(4):222-6
32. Wang G, Liu XG, Zitsman JL. Nonfluoroscopic reduction of intussusception by air enema. *World J Surg* 1995 May-Jun;19(3): 435 - 8
33. Gu L, Zhu H, Wang S, Han Y, Wu X, Miao H. Sonographic guidance of air enema for intussusception reduction in children. *Pediatr Radiol* 2000 May; 30(5): 339 - 42
34. Rubi I, Vera R, Rubi SC, Torres EE, Luna A, Arcos J, Paredes R, Rodriguez J, Velasco B, Garcia M. Air reduction of intussusception. *Eur J Pediatr Surg* 2002 Dec;12(6): 387 - 90