

Indications and accuracy of ophthalmic ultrasonography in King Chulalongkorn Memorial Hospital*

Prasart Laksanaphuk** Tasaporn Yarnwit**
Suppapong Tirakunwichcha** Bharkbhum Khambhiphant**
Ponthep Suntharo** Parnchat Pukrushpan**
Sirichai Pasadhika** Wasee Tulvatana**

Laksanaphuk P, Yarnwit T, Tirakunwichcha S, Khambhiphant B, Suntharo P, Pukrushpan P, Pasadhika S, Tulvatana W. Indications and accuracy of ophthalmic ultrasonography in King Chulalongkorn Memorial Hospital. Chula Med J 2005 Aug; 49(8): 459 - 65

- Objective** : *To study the indications for ophthalmic ultrasonography and the accuracy in detecting or excluding retinal detachment in vitreous hemorrhage.*
- Design** : *Retrospective descriptive study*
- Settings** : *Ophthalmic Ultrasound Clinic, King Chulalongkorn Memorial Hospital.*
- Materials and Methods** : *Medical records of consecutive patients who underwent diagnostic A- and/or B-scan ophthalmic ultrasonography from June 2003 to May 2004 were reviewed. The requisitions for ultrasonography were evaluated. In patients with vitreous hemorrhage, the presence or absence of retinal detachment from ultrasonography was compared with the operative findings and clinical follow-up.*

* Presented in part at the Second SERI-ARVO Meeting on Research in Vision and Ophthalmology, February 16-20, 2005

** Department of Ophthalmology, Faculty of Medicine, Chulalongkorn University

- Results** : *During the study period, ultrasonography was performed in 347 eyes of 296 patients. Their age ranged from 3 months to 86 years. Complete records were obtained from 330 eyes. Indications for ophthalmic ultrasonography included corneal opacity (99 eyes, 30%), lens opacity (55 eyes, 16.7%), vitreous opacity (89 eyes, 27%), and others. Out of 56 cases with vitreous hemorrhage, only 36 eyes yielded their final clinical results. Ultrasonography was able to detect or exclude retinal detachment in 34 out of 36 eyes; the accuracy was 94%.*
- Conclusion** : *The most common indication for ophthalmic ultrasonography in King Chulalongkorn Memorial Hospital is corneal opacity. The accuracy to detect or exclude retinal detachment is high in patients with vitreous hemorrhage. Ultrasonography is a useful diagnostic tool for evaluating prognosis and facilitating the decision for further treatment.*
- Keywords** : *Ophthalmic ultrasonography, Indications, Vitreous hemorrhage, Retinal detachment, Accuracy.*

Reprint request: Laksanaphuk P. Department of Ophthalmology, Faculty of Medicine, Chulalongkorn University, Bangkok 10330, Thailand.

Received for publication. May 9, 2005.

ประศาสน์ ลักษณะพุกัก, ทัศนพร ญาณวิทย์, ศุภพงษ์ ธิรคุณวิชชะ, ภาคภูมิ คัมภีร์พันธุ์, พลเทพ สุนทรโร, ปานฉัตร ภักร์ชพันธุ์, สิริชัย ปาสาทิกา, วลี ตูลวรรธนะ. ข้อบ่งชี้และความแม่นยำในการตรวจตาด้วยคลื่นเสียงความถี่สูงในโรงพยาบาลจุฬาลงกรณ์. จุฬาลงกรณ์เวชสาร 2548 ส.ค; 49(8): 459 - 65

วัตถุประสงค์ : เพื่อศึกษาข้อบ่งชี้ในการส่งตรวจตาด้วยคลื่นเสียงความถี่สูงในโรงพยาบาลจุฬาลงกรณ์และเพื่อศึกษาความแม่นยำของการวินิจฉัยว่ามีหรือไม่มีจอประสาทตาลอกเฉพาะในรายที่มีเลือดออกในวุ้นตา

รูปแบบการวิจัย : การศึกษาเชิงพรรณนาแบบย้อนกลับ

สถานที่ : คลินิกตรวจตาด้วยคลื่นเสียงความถี่สูง โรงพยาบาลจุฬาลงกรณ์

วัสดุและวิธีการ : ค้นหะระเบียนผู้ป่วยที่เข้ารับการตรวจด้วยคลื่นเสียงความถี่สูงแบบเอและหรือบีสแกนเพื่อวินิจฉัยโรคตาในช่วงมิถุนายน 2546 ถึงพฤษภาคม 2547 เพื่อบันทึกข้อมูลการขอส่งตรวจและผลการตรวจ โดยในรายที่มีเลือดออกในวุ้นตา ได้ตรวจสอบความถูกต้องของการวินิจฉัยว่ามีหรือไม่มีจอประสาทตาลอกด้วยการเปรียบเทียบกับผลการผ่าตัดหรือการติดตามผู้ป่วย

ผลการศึกษา : ในช่วงที่ทำการศึกษานี้มีผู้ป่วยที่เข้ารับการตรวจจำนวน 296 คน 347 ตา โดยผู้ป่วยมีอายุระหว่าง 3 เดือนถึง 86 ปี ค้นได้ประวัติที่สมบูรณ์ของผู้ป่วย 330 ตา ข้อบ่งชี้ในการส่งตรวจ ได้แก่ กระจกตาขุ่น 99 ตา (30 %), แก้วตาขุ่น 55 ตา (16.7 %), วุ้นตาขุ่น 89 ตา (27 %), และอื่น ๆ ในผู้ป่วยที่มีเลือดออกในวุ้นตาจำนวน 56 ตานั้น มีเพียง 36 ตาที่สามารถสรุปผลทางคลินิกได้ ซึ่งพบว่าการตรวจตาด้วยคลื่นเสียงความถี่สูงในการแยกแยะจอประสาทตาลอก ให้ผลที่ถูกต้องถึง 34 ใน 36 ตา คิดเป็นความแม่นยำ 94 %

สรุป : ข้อบ่งชี้ที่พบบ่อยที่สุดในการส่งตรวจตาด้วยคลื่นเสียงความถี่สูงในโรงพยาบาลจุฬาลงกรณ์ ได้แก่ กระจกตาขุ่น การตรวจชนิดนี้ให้ผลดีในแง่ของความแม่นยำของการวินิจฉัยจอประสาทตาลอกโดยเฉพาะในรายที่มีเลือดออกในวุ้นตา จึงเป็นการตรวจที่มีประโยชน์ในการพยากรณ์โรค และการตัดสินใจให้การรักษาทางตาต่อไป

คำสำคัญ : คลื่นเสียงความถี่สูง, ข้อบ่งชี้, เลือดออกในวุ้นตา, จอประสาทตาลอก, ความแม่นยำ

Ophthalmic ultrasonography is a useful technique for detection and differentiation of many ocular and orbital disorders, regardless of intervening ocular media opacities. This painless and non-invasive procedure is also an important tool in the differentiation and management of intraocular tumor even when the media is clear. Although the ophthalmic ultrasonography is generally used in tertiary care hospitals, there have been no previous reports on the collective results of the procedure in Thailand. The purposes of this report were to study the indications to perform the ultrasonography and to determine the accuracy of the test in detecting or excluding retinal detachment in patients with vitreous hemorrhage.

Methods

The study protocol was approved by the Ethics Committee of the Faculty of Medicine, Chulalongkorn University. Medical records of consecutive 347 eyes from 296 patients undergoing diagnostic A-and/ or B-scan at the ultrasound clinic, King Chulalongkorn Memorial Hospital, between June 2003 and May 2004 were retrospectively evaluated. All cases were classified according to the indications for the examination. Diagnostic A-and/ or B-scan were carried out using multifunctional UD-6000 ultrasonic A/B scanner and biometer (Tomey Corporation, Nagoya, Japan). Complete examination was achieved with fine manual movements of the probe, and also by asking the patients to look in different gazes. Anterior chamber, lens, vitreous, optic disc, macula, retina, retinochoroidal thickness, the axial length, and scleral findings were reviewed. Data collection included sex, age, indications for ultrasonography, and the final clinical or operative findings. The

indications of requisition for ultrasonography were categorized into the following anatomical regions: corneal opacity, anterior chamber opacity, lens opacity, posterior synechiae, vitreous opacity, choroid, sclera, and others (i.e. trauma, congenital anomaly, optic nerve head drusen, and intraocular foreign body). The other outcome measurement was the accuracy to detect or exclude retinal detachment in cases of vitreous hemorrhage. Ultrasonographic records were evaluated to determine the presence or absence of retinal detachment. Clinical information was obtained from the medical records after the absorption of vitreous hemorrhage or following vitreous surgery. The accuracy was determined by comparing the ultrasound results with the final clinical findings retrieved from medical records and operative notes.

Results

The study included 347 eyes of 296 patients with their age range from 3 months to 86 years. According to gender distribution, 185 patients (62.5 %) were male; and 111 patients (37.5 %) were female. There were 17 eyes with missing data. Complete medical records were obtained from 330 eyes (95.1%). The most common indication for ultrasonography was corneal opacity. Other indications classified by anatomical regions are shown in Table 1.

Fifty-six eyes from 330 eyes (17 %) had vitreous hemorrhage. The most common cause of vitreous hemorrhage was diabetic retinopathy. Other known causes of vitreous hemorrhage were age-related macular degeneration, trauma, branch retinal vein occlusion, posterior vitreous detachment without break, retinal detachment, cytomegalovirus retinitis, and posterior vitreous detachment with break (Table 2).

Table 1. The indications for performing ophthalmic ultrasonography.

Indications	Number of eyes (%)
Corneal opacity	99 (30)
Anterior chamber opacity	6 (1.8)
Membrane	2
Hyphema	3
Hypopyon	1
Posterior synechiae	20 (6.1)
Lens opacity	55 (16.7)
Cataract	54
Posterior capsular opacity	1
Vitreous opacity	89 (27)
Vitreous hemorrhage	56
Vitreous opacity	19
Endophthalmitis	14
Choroidal and uveal lesions	23 (7)
Choroidal mass	10
Choroidal detachment	11
Choroidal hemorrhage	1
Iris cyst	1
Sclera	2 (0.6)
Scleral abscess	2
Others	36 (11)
Trauma	32
Congenital anomaly	1
Optic nerve head drusen	1
Rule out intraocular foreign body	2

Of 56 eyes with vitreous hemorrhage, 11 (19.6 %) were lost to follow up, 7 (12.5 %) were referred to other hospitals due to the socioeconomic problems, and 2 (3.6 %) were scheduled for surgery. Therefore, complete clinical results were obtained from 36 eyes (64.3 %): 22 eyes after the resolution of vitreous hemorrhage by conservative treatment, and 14 eyes

Table 2. Causes of vitreous hemorrhage from clinical diagnosis.

Causes of vitreous hemorrhage	Number of eyes (%)
Diabetic retinopathy	16 (28.6)
Age-related macular degeneration	8 (14.3)
Trauma	7 (12.5)
Branch retinal vein occlusion	5 (8.9)
Posterior vitreous detachment	3 (5.4)
without break	
Retinal detachment	3 (5.4)
Cytomegalovirus retinitis	3 (5.4)
Posterior vitreous detachment	2 (3.6)
with break	
Unknown	9 (16.1)

from operative records. The final clinical findings confirmed the ultrasonography findings in 34 (94 %) out of 36 eyes with vitreous hemorrhage. There were only 2 eyes in which ultrasonography failed to demonstrate the correct findings:

(1) Ultrasonography in a 44-year-old man with a vitreous hemorrhage from proliferative diabetic retinopathy (8 weeks after the onset of the hemorrhage) demonstrated multiple areas of localized tractional retinal detachment (Figure 1). During pars plana vitrectomy, membrane peeling, membrane cutting, and endophotocoagulation, the operative findings showed only old vitreous hemorrhage, fibrin, and fibrous bands. There was no retinal detachment detected.

(2) Ultrasonography in a 69-year-old woman with vitreous hemorrhage (6 weeks after the onset of the hemorrhage) demonstrated a retinal detachment secondary to age-related macular degeneration (Figure 2). Pars plana vitrectomy was performed, and the operative findings showed dense vitreous

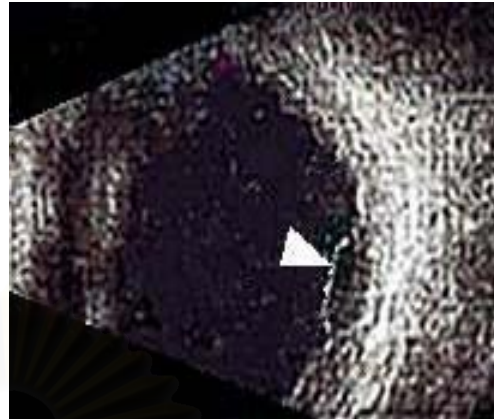
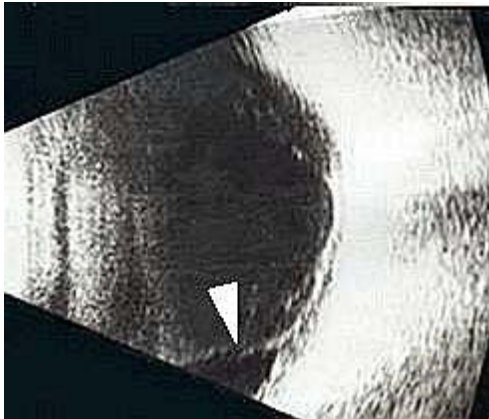


Figure 1. B-scan shows high echoic line (arrow) attached to the posterior pole resembling localized tractional retinal detachment.

Figure 2. B-scan shows high echoic line (arrow) resembling localized retinal detachment.

hemorrhage, tortuous vessels at disc, large drusen, and geographic atrophy at macula area, without retinal detachment.

From our results, the sensitivity of the test was 90 % (95 % CI, 46.3, 98.9). The specificity was 92.4 % (95 % CI 78.4, 97.6). The positive predictive value was 64.3 % (95 % CI 30.3, 88.2). The negative predictive value was 98.4 % (95 % CI 86.3, 99.8).

Discussion

Ultrasonography is a useful diagnostic tool in evaluating eye diseases by providing information regarding the diagnosis, prognosis, and even plans for treatment in some ocular diseases.^(1,2) Kinetic ultrasonography could provide information about the most suitable time to treat and thus obtain better anatomical and functional results in patients with vitreous hemorrhage.⁽³⁾ In this study, we have reviewed indications of the test in our practices, and also the accuracy in detecting or excluding the retinal detachment in cases of vitreous hemorrhage. The

most common indication for ultrasonography was corneal opacity (30 %). The findings contrast with the report from Ingrid et al,⁽⁴⁾ who reported that retinal tear or detachment was the most common indication (54 %). The discrepancy is not unusual, as the usage of the diagnostic test may differ in different settings.

The role of ultrasonography in the detection of retinal detachment in the eye with opaque media has been clearly established.⁽⁵⁾ So far there is no other efficient method to reliably ascertain the anatomical position of the retina when the direct examination is impossible. The presence of retinal detachment profoundly changes the management in this group of patients.⁽⁶⁾ Thus the accuracy is crucial, especially in patients with vitreous hemorrhage. In our study, ultrasonography correctly identified the anatomical position of the retina in 34 out of 36 eyes (94 %) with vitreous hemorrhage. The finding agreed with the previous reports from other institutions,⁽⁶⁻⁹⁾ where the preoperative ultrasonography correctly identified the anatomical position of the retina in

84 - 93.3 % of the eyes with vitreous hemorrhage. During the test, vitreoretinal adhesion and fibrovascular membrane are sometimes misinterpreted as retinal detachment. This is not uncommon, since the kinetic ultrasonography may yield a membrane related to the optic disc or other points on the retinal surface, which shows high echogenicity on ultrasonography, with or without after movement. These findings may be misdiagnosed as retinal detachment. The timing of ultrasonography may have the interference with the results as well. False positive results may occur in longstanding vitreous hemorrhage, where dense vitreous hemorrhage with incomplete PVD can be mistakenly interpreted as detached retina. In this study, we found that two eyes were falsely diagnosed as having retinal detachment. Timing of ultrasonography was 6 to 8 weeks after the onset of vitreous hemorrhage.

A major limitation of this study was its retrospective nature. There were some missing data. The clinical findings could not be completely retrieved in some cases. Future prospective study with a thorough plan may better explore the impact of ultrasonography on the evaluation and management of ocular diseases.

In conclusion, the most common indication for ophthalmic ultrasonography in King Chulalongkorn Memorial Hospital is corneal opacity. In vitreous hemorrhage, the accuracy to detect or exclude retinal detachment is high. Ultrasonography is a useful diagnostic tool for evaluating prognosis and facilitating the decision for further treatment in various eye diseases.

References

1. McLeod D, Restori M. Ultrasonic examination in

severe diabetic eye disease. *Br J Ophthalmol* 1979 Aug; 63(8): 533-8

2. Coleman DJ, Franzen LA. Vitreous surgery; preoperative evaluation and prognostic value of ultrasonic display of vitreous hemorrhage. *Arch Ophthalmol* 1974 Nov; 92(5): 375-81
3. Capeans C, Santos L, Tourino R, Otero JL, Gomez-Ulla F, Sanchez-Salorio M. Ocular echography in the prognosis of vitreous haemorrhage in type II diabetes mellitus. *Int Ophthalmol* 1997-98; 21(5): 269-75
4. Scott IU, Smiddy WE, Feuer WJ, Ehliel FJ. The impact of echography on evaluation and management of posterior segment disorders. *Am J Ophthalmol* 2004 Jan; 137(1): 24-9
5. Blumenkranz MS, Byrne SF. Standardized echography (ultrasonography) for the detection and characterization of retinal detachment. *Ophthalmology* 1982 Jul; 89(7): 821-31
6. Rabinowitz R, Yagev R, Shoham A, Lifshitz T. Comparison between clinical and ultrasound findings in patients with vitreous hemorrhage. *Eye* 2004 Mar; 18(3): 253-6
7. Jack RL, Hutton WL, Machemer R. Ultrasonography and vitrectomy. *Am J Ophthalmol* 1974 Aug; 78(2): 265-74
8. Jalkh AE, Avila MP, El-Markabi H, Trempe CL, Schepens CL. Immersion A- and B-scan ultrasonography. Its use in preoperative evaluation of diabetic vitreous hemorrhage. *Arch Ophthalmol* 1984 May; 102(5): 686-90
9. Kumar A, Verma L, Jha SN, Tewari HK, Khosla PK. Ultrasonic errors in analysis of vitreous hemorrhage. *Indian J Ophthalmol* 1990 Oct-Dec; 38(4):162-3